



Background

Quantitative glaucoma indices commonly rely on geometric parameters of the optic nerve head (ONH) such as disk area or cup volume.

However, the ONH is a too complex structure to be accurately analyzed by geometric morphometry because of:

- **Sparse** sampling of ONH
- Lack of mathematically derived and biologically interpretable ONH descriptions [2]

Purpose

We provide **dense** descriptions of the ONH variability in glaucomatous cases presented by tissue deformations.

Data

Erlangen Glaucoma Registry (Figure 1)

- Color fundus photographs (Kowa non-myd, FOV 22.5°, ONH centered)
- Gold standard for glaucoma diagnosis is present
 - Diagnosis by an experienced ophthalmologist
 - Complete ophthalmological examination (ophthalmoscopy, visual field test, IOP, FDT, HRT II)

Dataset characteristics

- Mean age 55.4 ± 10.9 years
- ONH area $2.2 \pm 0.5 \text{ mm}^2$ (Macro ONH not included)
- 149 glaucoma cases I_g (FDT test time 67.4 ± 35.6 s)
- 246 controls I_c

Methods

1. Fundus image preprocessing [1]

Normalized optic nerve head images by eliminating disease independent variations (Figure 1) such as

- illumination inhomogeneities
- ONH normalization
- vessel structures.

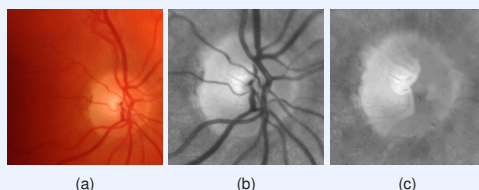


Figure 1: Preprocessing to eliminate disease independent variations: (a) cropped original fundus image, (b) illumination corrected reflectance image with normalized ONH location, (c) inpainted vessel structures.

2. Non rigid image registration

Characterization of inter subject ONH variability by dense deformation fields U calculated between one reference image R and image samples $T \in I$

- Variational multilevel approach $D(R(U), T) + s \cdot S(U) \xrightarrow{u} \min$
- Distance measure D : Sum of squared differences
- Smoother S : Diffusion regularizer

3. Deformation based reference ONH

ONH reference image R that is characterized by the **minimal average residual deformation** over a sample set I is calculated by an iterative procedure:

- Reference R : Selection of initial estimate as the average of sample set I
- Calculation of deformation fields U_i between samples I_i and current reference R
- Average deformation field: $U_{avg} = \frac{1}{N} \sum_{i=0}^N U_i$
- Deformation of reference $R(U_{avg})$ by average deformation field U_{avg}

4. Isolation of abnormal variations

from captured deformation field which is distorted by overlaid control deformations.

- Deformation field U between reference ONH R and a sample
- Model healthy ONH variability by Principal Component Analysis (PCA) on deformation fields U of controls I_c
- Crop deformations by the fraction represented by PCA model of controls

5. Statistical deformation model (SDM) of ONH

to provide a mathematically derived and biologically interpretable description of ONH variability in glaucomatous optic atrophy.

- PCA model on deformations U of
 - control samples I_c
 - glaucomatous cases I_g
- Supervised attribute selection on modes
 - Identification of modes most discriminating between controls and glaucomatous

Results and Discussion

1. Deformation based reference ONH




Figure 2: Comparison of pixel wise averaging (a,b) and deformation based averaging (c,d) of ONH reflectance images: (a,c) control, (b,d) glaucoma. Pixel wise averages (a,b) are too smooth to identify local structures. Deformation based averaging (c,d) clearly shows a structural thinning of the upper rim in case of glaucoma (d) compared to control reference (c) (red arrows).

2. Isolation of abnormal deformations




Figure 3: Isolation of abnormal deformations: (a,b) control, (c,d) glaucoma. (a,c) Captured deformations between test sample and reference. Abnormal deformations overlaid by high amount of control deformations. (b,d) Isolated abnormal deformations showing an increased cupping for the glaucomatous case (d). (red: high magnitude, blue: low magnitude of deformation vector)

- Visualization of ONH's deformations
- Identification of isolated abnormal deformations
 - Novel representation for the physician
- 3. **SDM of ONH in glaucoma**
 - Discriminative modes identify patterns of variation
 - Intuitive visualization of ONH deformation (Figure 4)
 - Mathematically derived influence of rim and cup
- Biologically interpretable descriptions of ONH deformation in case of glaucoma

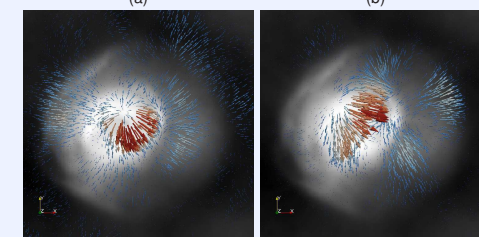
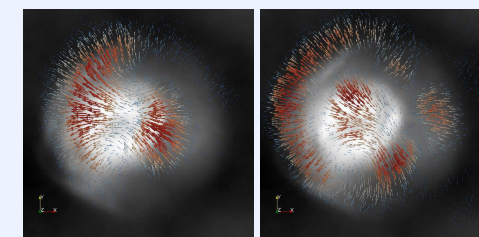


Figure 4: First four PCA modes most discriminating between control and glaucoma providing a mathematically derived and biologically interpretable description of ONH deformations: (a,b) Simultaneous deformation of the cup and rim, (c,d) local extension of the cup (red: high magnitude, blue: low magnitude of deformation vector).

Conclusion

- Statistical deformation modelling of ONH provides
 - intuitive representation of ONH variability
 - main modes of glaucomatous deformations
 - identification of abnormal deformations.

Deformation based morphometry of ONH shows a potential to be a **future** technique to gain novel insights into glaucomatous changes of the ONH.

Support

This contribution was supported by the German National Science Foundation (DFG) in the context of Collaborative Research Center 539. The authors gratefully acknowledge funding of the Erlangen Graduate School in Advanced Optical Technologies (SAOT) by the German National Science Foundation (DFG) in the framework of the excellence initiative. We thank V. Daum for providing the non rigid registration framework.

Commercial Relationship

R. Bock, None; J. Hornegger, None; G. Michelson, None.

References

[1] R. Bock, J. Meier, L. G. Nyúl, J. Hornegger, G. Michelson. Glaucoma risk index: Automated glaucoma detection from color fundus images. *Med Image Anal*, 14(3), 471-481, 2010.

[2] P.G. Sanfilippo, A. Cardini, A. W. Hewitt, J. G. Crowston, D. A. Mackey. Optic disc morphology - Rethinking shape. *Progress in Retinal and Eye Research*, 28(4), 227-248, 2009.