

Automatic measurement of contrast bolus distribution in carotid arteries using a C-arm angiography system to support interventional perfusion imaging

Andreas Fieselmann^{a,b,c}, Arundhuti Ganguly^d, Yu Deuerling-Zheng^c, Jan Boese^c,
Joachim Hornegger^{a,b}, Rebecca Fahrig^d

^aDepartment of Computer Science, Pattern Recognition Lab, Friedrich-Alexander University of Erlangen-Nuremberg, Martensstr. 3, 91058 Erlangen, Germany;

^bErlangen Graduate School in Advanced Optical Technologies (SAOT), Erlangen, Germany;

^cSiemens AG, Healthcare Sector, Siemensstr. 1, 91301 Forchheim, Germany;

^dDepartment of Radiology, Stanford University, 1201 Welch Road, Palo Alto, CA 94305, USA

ABSTRACT

Brain perfusion CT using a C-arm angiography system capable of CT-like imaging could optimize patient treatment during stroke therapy procedures. For this application, an intra-arterial contrast bolus injection at the aortic arch could be used provided that the location of the injection catheter enables uniform distribution of the bolus into the two common carotid arteries (CCA). In this work, we present a novel method to support optimal injection catheter placement by providing additional quantitative information about the distribution of the contrast bolus into the CCAs. Our fully automatic method uses 2-D digital subtraction angiography (DSA) images following a test bolus injection. It segments both CCAs and computes the relative contrast distribution. We have tested the method in DSA data sets from 5 healthy pigs and our method achieved successful segmentation of both CCAs in all data sets. The results showed that the contrast is uniformly distributed (mean relative difference less or equal than 10%) if the injection location is properly chosen.

Keywords: DSA, contrast bolus, C-arm, perfusion imaging, stroke

1. INTRODUCTION

Brain perfusion CT and MR are common methods for stroke diagnosis and consist of a contrast bolus injection and sequential scanning of the brain to measure the contrast bolus flow.¹ With a C-arm angiography system capable of CT-like imaging it could be possible to measure tissue perfusion in the interventional suite.² This could lead to optimized patient treatment by providing intra-procedural perfusion information.

Since it is expected that the patient is catheterized for vascular therapy an arterial contrast bolus injection would be feasible in perfusion C-arm CT imaging. This would not be preferred in perfusion CT and MR where intra-venous contrast bolus injections are used. An arterial injection increases the fraction of contrast that reaches the brain and thus can increase the signal-to-noise ratio of the measured contrast curves or decrease the needed amount of injected contrast compared to an intra-venous injection.

In clinical practice, stroke diagnosis from perfusion CT images is performed by comparing the perfusion maps of the two hemispheres. Hence, it is necessary that the contrast flowing into the two sides has the same characteristics and that the contrast bolus is distributed equally between both common carotid arteries (CCA). Another important aspect is the mixability of the contrast with blood after an intra-arterial injection. In a recent study, Lieber et al.³ demonstrated that using a typical intra-arterial contrast injection the contrast mixes with the blood within ten artery diameters downstream of the catheter tip.

To address the topic of uniform contrast distribution into the CCAs, we will present an automatic, robust and fast method that quantifies the contrast bolus distribution following a test bolus injection from DSA images. This information could optimize exact placement of the injection catheter during the intervention and improve perfusion C-arm CT imaging.

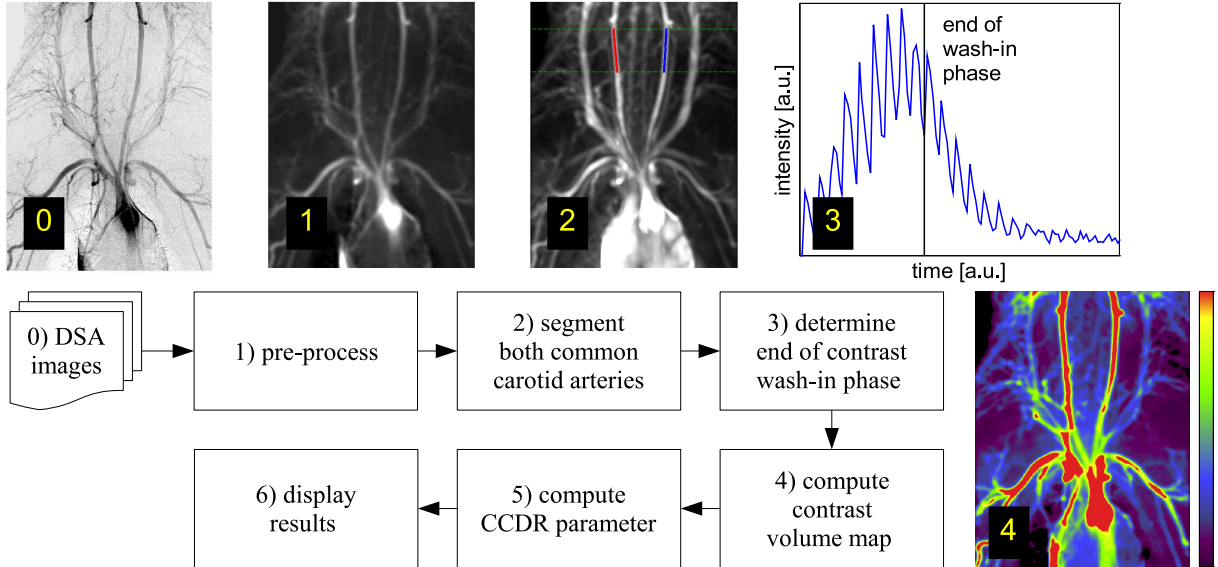


Figure 1. Overview of the algorithm to measure the contrast bolus distribution in the common carotid arteries (CCA).

2. DESCRIPTION OF THE ALGORITHM

In this section, we will explain our algorithm to measure the contrast bolus distribution in the CCAs. Figure 1 depicts an overview of the algorithm. After pre-processing of the raw data (step 1), the CCAs are segmented fully automatically (step 2). In step 3, the end of the contrast wash-in phase is determined from the time-intensity curves of the CCAs. This information is necessary to compute the so-called contrast volume map in step 4. In step 5 the contrast volume map and the segmentation result of the CCAs are used to compute the carotid contrast distribution ratio (CCDR) parameter.

2.1 Pre-processing

The first step of our algorithm is the pre-processing of the measured data. We introduce the variable $P_{\text{sub}}(u, v, t)$ to denote the baseline-subtracted projection values at the pixel area with size $\Delta u \Delta v$ centered at the detector coordinates (u, v) . The baseline subtraction is accomplished by subtraction of the projection value before contrasts enters the field of view. To convert the measured photon flux density into line integrals of attenuation values, i.e. projection values, a logarithmic transform and a change of sign must be applied. To reduce noise, we apply a 2-D spatial Gaussian filter with standard deviation of 2.5 mm to all time instances of $P_{\text{sub}}(u, v, t)$.

2.2 Segmentation of Carotid Arteries

We segment the common carotid arteries from a temporal maximum intensity projection (tMIP) of $P_{\text{sub}}(u, v, t)$ which we denote as $P_{\text{tMIP}}(u, v)$. First, we apply a spatio-temporal weighting of $P_{\text{tMIP}}(u, v)$ to increase the intensity of the CCAs relative to other structures. The combined weighting function $w_{\text{cmb}} \in [0, 1]$ has a factor $w_{\text{spt}} \in [0, 1]$ that uses prior knowledge of the spatial position of the CCA and a factor $w_{\text{tmp}} \in [0, 1]$ that uses prior knowledge of the expected temporal contrast dynamics. The weighted tMIP, denoted by $P_{\text{tMIP}}^w(u, v)$, is then given by

$$\begin{aligned}
 P_{\text{tMIP}}^w(u, v) &= w_{\text{cmb}}(u, v) P_{\text{tMIP}}(u, v) \\
 &= w_{\text{spt}}(u) w_{\text{tmp}}(u, v) P_{\text{tMIP}}(u, v) .
 \end{aligned} \tag{1}$$

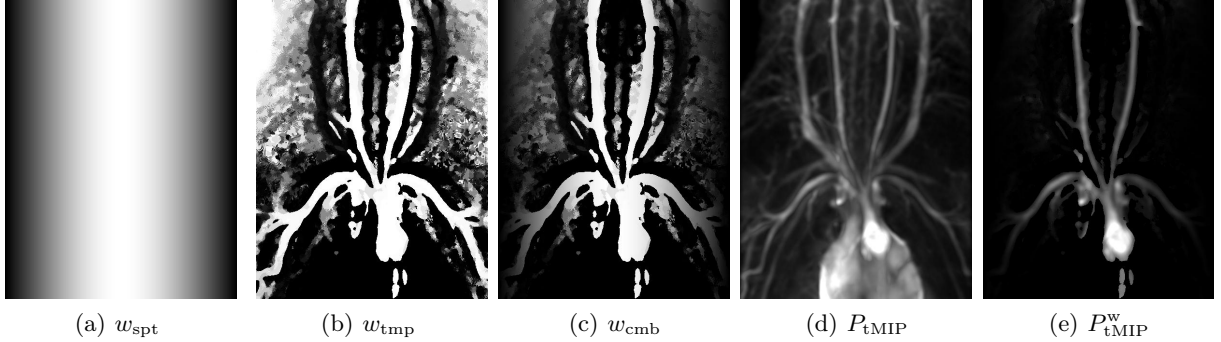


Figure 2. (a-c) Spatial (w_{spt}), temporal (w_{tmp}) and combined (w_{cmb}) weighting functions. The windowing is from 0 (black) to 1 (white). (d-e) Unweighted tMIP (P_{tMIP}) and tMIP weighted with w_{cmb} (P_{tMIP}^w). Both tMIPs have the same windowing from 0 (black) to the half maximum of the image data corresponding to (d) (white).

The weighting functions $w_{\text{spt}}(u)$ and $w_{\text{tmp}}(u, v)$ will be described next. The spatial weighting assumes that the CCAs can be found near the center of the image. Using a 1-D Gaussian function $G_f(x)$,

$$G_f(x) = \exp\left(-\left(\frac{2\sqrt{\ln(2)}}{f}x\right)^2\right), \quad (2)$$

where the parameter f controls the full width at half maximum, it is defined as

$$w_{\text{spt}}(u) = 2G_U(u - u_0) - 1. \quad (3)$$

Here, U is the total width of the detector and u_0 is the center coordinate of the detector, both with respect to the u -coordinate. See Figure 2(a) for an example of $w_{\text{spt}}(u)$. Different smooth weighting functions could also be used, of course.

The temporal weighting assumes that the contrast arrives earlier in the arteries than in the draining veins. By $t_{\text{max},e}$ we denote the expected time-to-peak value of the time-intensity curve measured in the CCAs. This value can be chosen relative to the duration T_{inj} of the contrast injection. For example, we can set it to $t_{\text{max},e} = 1.2T_{\text{inj}}$. The temporal weighting function $w_{\text{tmp}}(u, v)$ is then defined as

$$w_{\text{tmp}}(u, v) = \begin{cases} 1 & , \text{ for } t_{\text{max}}(u, v) < t_{\text{max},e} \\ G_{t_{\text{max},e}}(t_{\text{max}}(u, v) - t_{\text{max},e}) & , \text{ for } t_{\text{max}}(u, v) \geq t_{\text{max},e} \end{cases} \quad (4)$$

$$t_{\text{max},e}(u, v) = \arg \max_t (P_{\text{sub}}(u, v, t)). \quad (5)$$

An example for $w_{\text{tmp}}(u, v)$ is shown in Figure 2(b).

For our following analysis, we do not require a complete segmentation of the CCAs. Thus, we segment the CCAs only in a region of interest (ROI) where $v \in [v_c - v_w, v_c + v_w]$. We use the parameters $v_w = 60$ mm and $v_c = v_{\text{max,cran}} - v_w$ where $v_{\text{max,cran}}$ is the v -coordinate at the cranial end of the image. These parameters have been chosen empirically and work well for typical DSA data sets acquired at the aortic arch. In the future, a more adaptive ROI selection may be used. See Figure 3 for a graphical visualization of the boundaries of the ROI.

The centerlines of the two CCAs can be segmented in the ROI of the image $P_{\text{tMIP}}^w(u, v)$ using standard 2-D vessel centerline segmentation methods.^{4,5} We use a simple technique that looks for the 2 highest intensity values, separated by a minimum distance of 5 mm, along the line in the u -direction for a given v -coordinate. Two paths are created by connecting the coordinates of these maxima starting from a maximum at the left and right side respectively. See Figure 3 for an example of the segmentation.

2.3 Computation of Contrast Volume Map

We introduce the contrast volume map (CVM) as a relative measure to estimate the amount of contrast agent that has flowed through a certain region. In particular, the CVM is used to compute the carotid contrast distribution ratio (CCDR) in Section 2.4. We assume that the measured baseline-subtracted projection value $P_{\text{sub}}(u, v, t)$ is proportional to the total mass of contrast at time t that is intersected by the X-rays from the source to the pixel centered at (u, v) .⁶

First, we determine the duration $T_{\text{wash, in}}$ of the contrast wash-in phase. It can be determined relative to the average time-to-peak measured inside the CCAs ($t_{\text{max, cca}}$). For example, we can set it to $T_{\text{wash, in}} = t_{\text{max, cca}} + 1\text{s}$ where s denotes seconds. Then, we compute the CVM, denoted by $P_{\text{cvm}}(u, v)$, as

$$P_{\text{cvm}}(u, v) = \int_0^{T_{\text{wash, in}}} P_{\text{sub}}(u, v, t) dt . \quad (6)$$

We limit the integration interval to the wash-in phase to fulfill the condition that the measured data $P_{\text{sub}}(u, v, t)$ has only contributions from a single vessel. The CVM can be displayed for a visual assessment of relative contrast bolus distribution. A quantitative evaluation of the CVM is done by computing the CCDR, as described in the next section.

2.4 Computation of Bolus Distribution

The carotid contrast distribution ratio (CCDR) is computed using the segmented centerlines of the CCAs and the contrast volume map (CVM). For each v -coordinate in the ROI, $v \in [v_c - v_w, v_c + v_w]$, we have a u -coordinate for the segmented centerline of the left CCA (u_1) and the right CCA (u_2). For a given v -coordinate we can approximate the v -specific CCDR as

$$\text{CCDR}_v \approx P_{\text{cvm}}(u_1(v), v) / P_{\text{cvm}}(u_2(v), v) . \quad (7)$$

Assuming similar flow characteristics in the left and right CCA, we can use this definition of the CCDR as a measure for the relative contrast bolus distribution into both carotids. A more theoretical analysis of the contrast bolus distribution is the subject of future investigation.

The final CCDR values are computed by averaging over the values obtained using the different v -coordinates.

3. EXPERIMENTAL EVALUATION

3.1 Material and Methods

We tested our algorithm using DSA sequences acquired as part of our perfusion studies under an institutionally-approved protocol in 5 anesthetized healthy pigs (54.1 ± 4.7 kg).² The DSA sequences, acquired at 7.5 frames per second, were used during the study for visual assessment of contrast flow uniformity and, in this work, we analyzed them retrospectively to compute quantitative parameters. For potential future patient studies we expect only slight adaption of the algorithm to the human anatomy.

A contrast bolus (Iohexol, 350 mgI/ml) was delivered intra-arterially at the root of the aortic arch using a 5-French diffusion catheter at different injection rates (3, 6, 9 ml/s). Contrast concentrations (33%-100%) were adjusted for each injection rate to provide a similar total contrast volume. We also investigated different catheter positions for one injection rate (3 ml/s).

3.2 Results

The centerline segmentation of the CCAs succeeded in all data sets, as determined by visual assessment. Hence, quantitative information about contrast distribution could be computed in all data sets.

For different injection rates (IR), the mean and standard deviation of the CCDR values were 0.99 ± 0.14 (3 ml/s IR), 1.10 ± 0.13 (6 ml/s IR) and 1.06 ± 0.10 (9 ml/s IR). When the catheter was pulled backward by 5-10 mm from its original position it was 0.26 ± 0.10 (3 ml/s IR). Catheter positions that were rated optimal during the perfusion studies had, in this retrospective analysis, CCDR values closer to one.

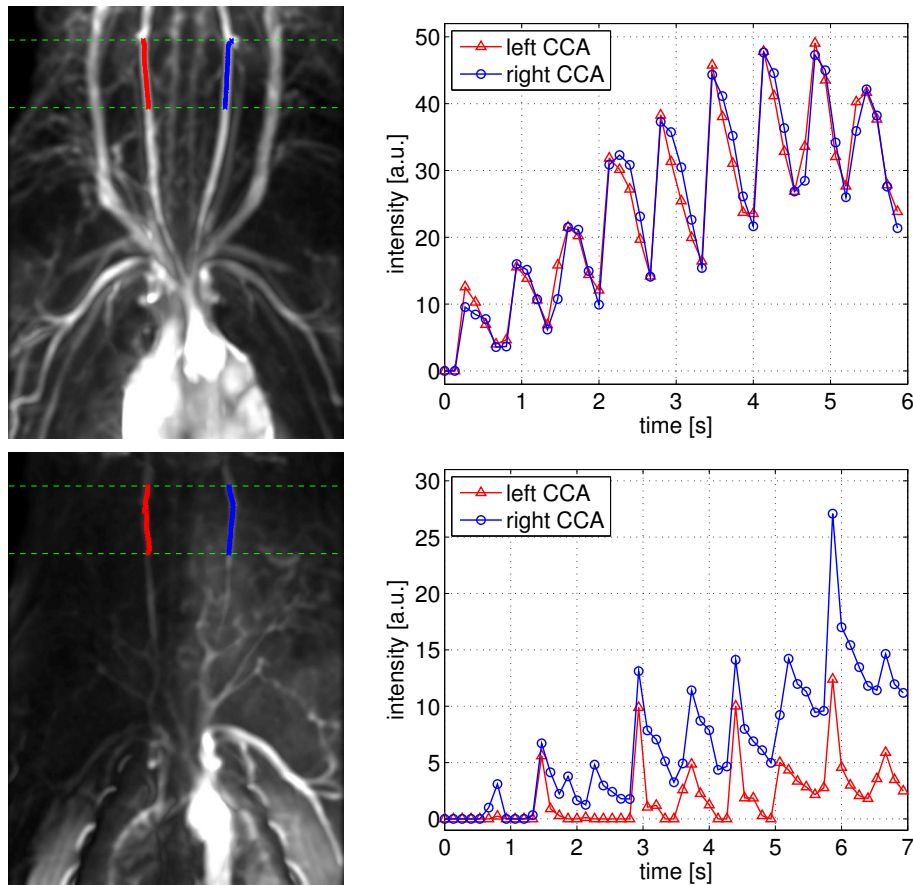


Figure 3. Segmentation of the two common carotid arteries (CCA) and plot of the time-intensity curve extracted from the CCAs. The segmentation is overlaid on a temporal maximum intensity projection of the 2-D DSA data set. Note that, the terms left and right CCA refer to the position in the image and not to the anatomical position; i.e. the left CCA of the pig is actually shown on the right side of the image.

Figure 3 shows segmentations of the CCA and extracted time-intensity curves from one pig with different injection catheter locations. Quantitative results for this example were $CCDR=1.03$ (top row) and $CCDR=0.36$ (bottom row). While the catheter position in the upper image provides uniform contrast bolus distribution, the catheter position in the bottom image results in a non-uniform bolus distribution.

4. DISCUSSION AND CONCLUSION

We presented a novel method for automatic quantitative evaluation of contrast distribution in the CCAs after a test bolus injection using DSA images. This method includes an automatic segmentation of the CCAs and an automatic image analysis to compute relevant parameters of the contrast volume distribution. The results of this study show that the contrast is uniformly distributed (mean relative difference $\leq 10\%$) into the CCAs if the injection location is selected properly. However, a larger sample size is necessary to prove this hypothesis.

The segmentation approach for the centerline of the CCA could also be adapted to other clinical applications or applied to other vessels in 2-D DSA sequences.

If used in clinical practice, our novel method could help to optimize the catheter placement for arterial injections in perfusion C-arm CT imaging during stroke therapy by providing additional quantitative parameters. Our novel method is robust, fast, user-independent and would not require extra X-ray or iodine dose compared to the current protocols which already use a test bolus injection with a pure visual assessment of the contrast flow.

ACKNOWLEDGMENTS

This work was supported by a research grant from Siemens AG, Healthcare Sector, Forchheim, Germany. Financial support was also provided through NIH 1K99EB007676 and the Lucas Foundation. The authors gratefully acknowledge funding of the Erlangen Graduate School in Advanced Optical Technologies (SAOT) by the German Research Foundation (DFG) in the framework of the German excellence initiative. Helpful discussions with Dr. M. Kowarschik, Siemens AG, are gratefully acknowledged.

REFERENCES

- [1] Shetty, S. K. and Lev, M. H., [*Acute Ischemic Stroke: Imaging and Intervention*], ch. CT Perfusion (CTP), 87–113, Springer, Berlin, Germany, 1st ed. (2006).
- [2] Ganguly, A., Fieselmann, A., Marks, M., Rosenberg, J., Boese, J., Deuerling-Zheng, Y., Straka, M., Zaharchuk, G., Bammer, R., and Fahrig, R., “Cerebral CT perfusion using an interventional C-arm imaging system: Cerebral blood flow measurements,” *American Journal of Neuroradiology* (2011). (accepted for publication).
- [3] Lieber, B. B., Sadasivan, C., Hao, Q., Seong, J., and Cesar, L., “The mixability of angiographic contrast with arterial blood,” *Medical Physics* **36**(11), 5064–5078 (2009).
- [4] Kirbas, C. and Quek, F., “A review of vessel extraction techniques and algorithms,” *ACM Computing Surveys* **36**(2), 81–121 (2004).
- [5] Schuldhaus, D., Spiegel, M., Redel, T., Polyanskaya, M., Struffert, T., Hornegger, J., and Dörfler, A., “2-D vessel segmentation using local adaptive contrast enhancement,” in [*Proc. Bildverarbeitung für die Medizin 2011*], Lübeck, Germany (2011). (to appear).
- [6] Dawson, P., [*Textbook of Contrast Media*], ch. Functional and physiological imaging, 75–94, Informa Healthcare, London, UK, 1st ed. (1999).