

Intraprocedural three dimensional reconstruction of the coronary sinus improves left ventricular lead

K. Gutleben¹, G.N. Noelker², H.M. Marschang¹, M.S. Schmidt¹, G.R. Ritscher¹, C.R. Rohkohl³, J.B. Brachmann¹, A.M.S. Sinha¹

¹ Klinikum Coburg, Coburg, Germany; ² Herz und Diabeteszentrum NRW, Bad Oeynhausen, Germany; ³ Friedrich-Alexander-Universität, Erlangen, Germany

Gutleben K, Noelker GN, Marschang HM, Schmidt MS, Ritscher GR, Rohkohl CR, Brachmann JB, Sinha AMS. Intraprocedural three dimensional reconstruction of the coronary sinus improves left ventricular lead. *Europace Journal* 2009, 11(Supplement 2), Abstract 538.

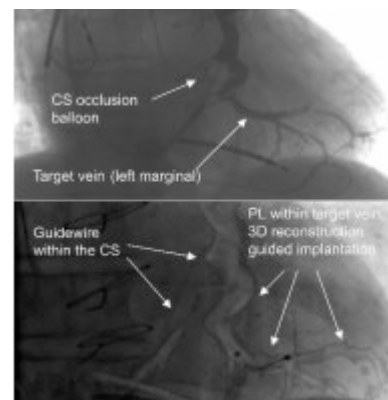
Introduction: Despite the use of standard angiography projections (SAP) of the coronary sinus (CS), left ventricular pacing lead (PL) placement can fail due to lacking information on the CS anatomy. Rotational angiography (RA) provides more information. We present for the first time intraprocedural three dimensional (3D) CS reconstruction from RA, and 3D image guided CS-PL implantation, using the syngo DynaCT Cardiac.

Methods: In 12 patients (11 m, 67±11 y) with indication for cardiac resynchronization therapy intraprocedural RA and 3D CS reconstructions were performed. After identifying the target vein from RA we measured CS-to-target vein angles and compared values from orthogonal RA view to values from SAP (RAO 20°, LAO 40°) and orthogonal 3D-view. PL placement was guided by RA, and 3D image integration into real time fluoroscopy.

Results: All implantation procedures were successful. Target veins were left marginal vein (n=5) and posterior left ventricle vein (n=7). CS-to-target vein angles obtained from RA view showed differences of 5.1±14.5° compared to RAO 20°, 11.0±32.6° to LAO 40°, and 1.8±14.6° to 3D reconstruction view. 3D image integration into real time fluoroscopy is depicted in figure 1.

Conclusions: Intraprocedural 3D reconstruction of the CS is feasible. CS-to-target vein angles measured by 3D are comparable to RA. Additionally, caudal and cranial views of the CS are provided. Image integration into real time fluoroscopy is helpful in PL placement.

Key Words: Technical and imaging aspects
(Resynchronization therapy)



3D-guided
CS-lead implantation