Noise and Artifact Reduction in Flat Detector CT Perfusion Imaging

Michael Manhart[1,2)]

Yu Deuerling-Zheng [3)], Andè Aichert[1,2)], Markus Kowarschik[3)], Andreas Maier[2)]
Tobias Struffert[1)], Joachim Hornegger[2)], Arnd Dörfler[1)]

1) Department of Neuroradiology, Universitätsklinikum Erlangen, Germany
2) Pattern Recognition Lab, FAU Erlangen-Nürnberg, Germany
3) Siemens AG, Angiography & Interventional X-Ray Systems, Germany

Workshop on Iterative Reconstruction with Compressed Sensing

January, 20th 2014

Universitätsklinikum Erlangen

SIEMENS

FRIEDRICH-ALEXANDER UNIVERSITÄT ERLANGEN-NÜRNBERG
TECHNISCHE FAKULTÄT

1. Flat Detector CT Perfusion
2. Digital Brain Perfusion Phantom
3. Reconstruction & Noise Reduction
4. Numerical Study: Digital Brain Phantom
5. Clinical Patient Studies

Flat Detector CT Perfusion

- CT Perfusion (CTP) quantifies blood flow in brain for diagnosis of ischemic stroke
- New treatment options for stroke: catheter guided therapy in interventional room
- Flat Detector CTP: monitor perfusion before and during intervention using C-arm system

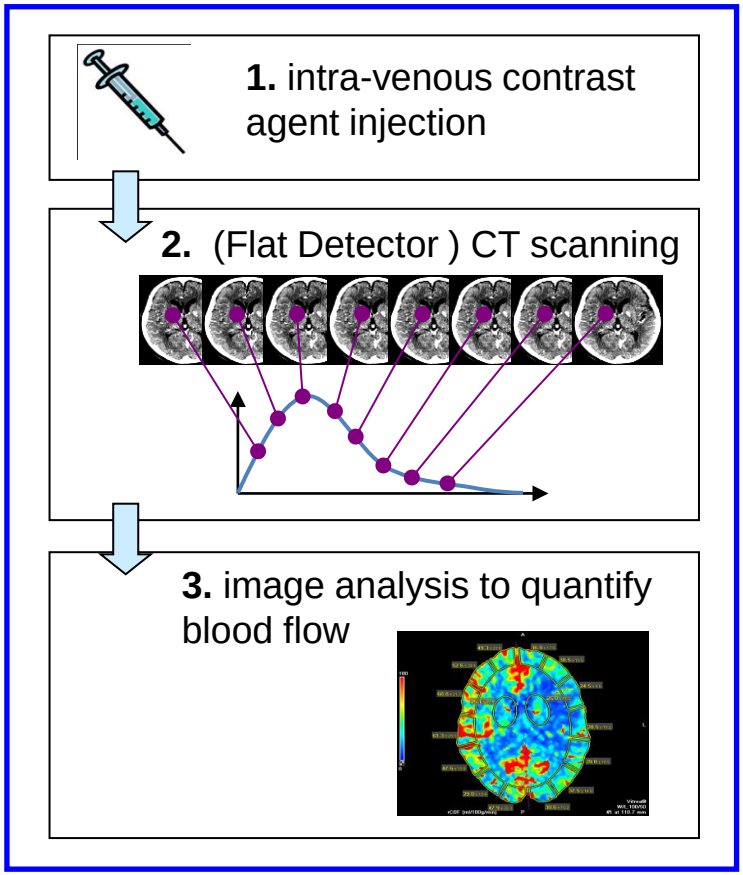

Scanning Protocols

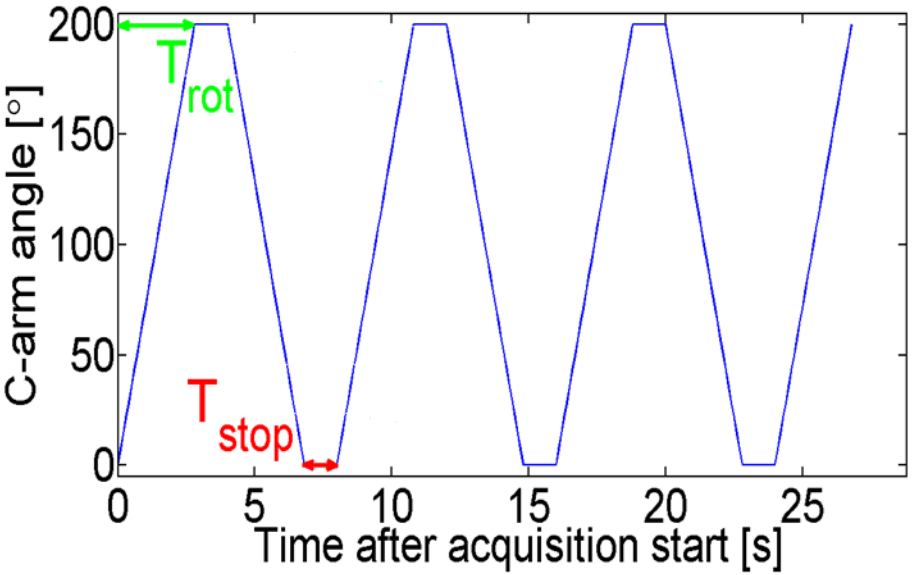

Challenges:

- Low C-arm acquisition speed (3.6-5.5 s / 200° incl. pause)
- **Angular under-sampling (133-248 projections / 200°)**
- **Low contrast-to-noise ratio in brain tissue (peak 5-30 HU)**
- **Patient motion**

Scanning Protocols

- 5 s Protocol with bi-plane C-arm system
  - 2 Mask Rotations
  - 7 Bolus Rotations
  - 248 Projections / Rotation
  - 4.2 s / Rotation
  - 1 s Pause between Rotations

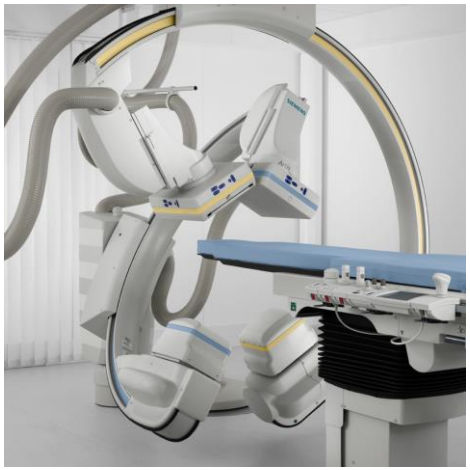

- 3 s Protocol with robotic C-arm system
  - 2 Mask Rotations
  - 10 Bolus Rotations
  - 133 Projections / Rotation
  - 2.6 s / Rotation
  - 1 s Pause between Rotations

1. Flat Detector CT Perfusion
2. Digital Brain Perfusion Phantom
3. Reconstruction & Noise Reduction
4. Numerical Study: Digital Brain Phantom
5. Clinical Patient Studies

Dynamic Brain Phantom - Time Curves

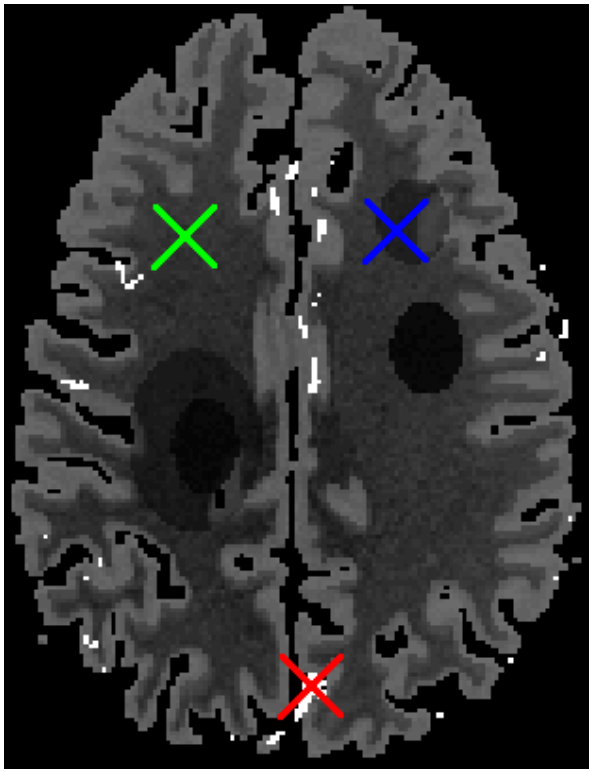

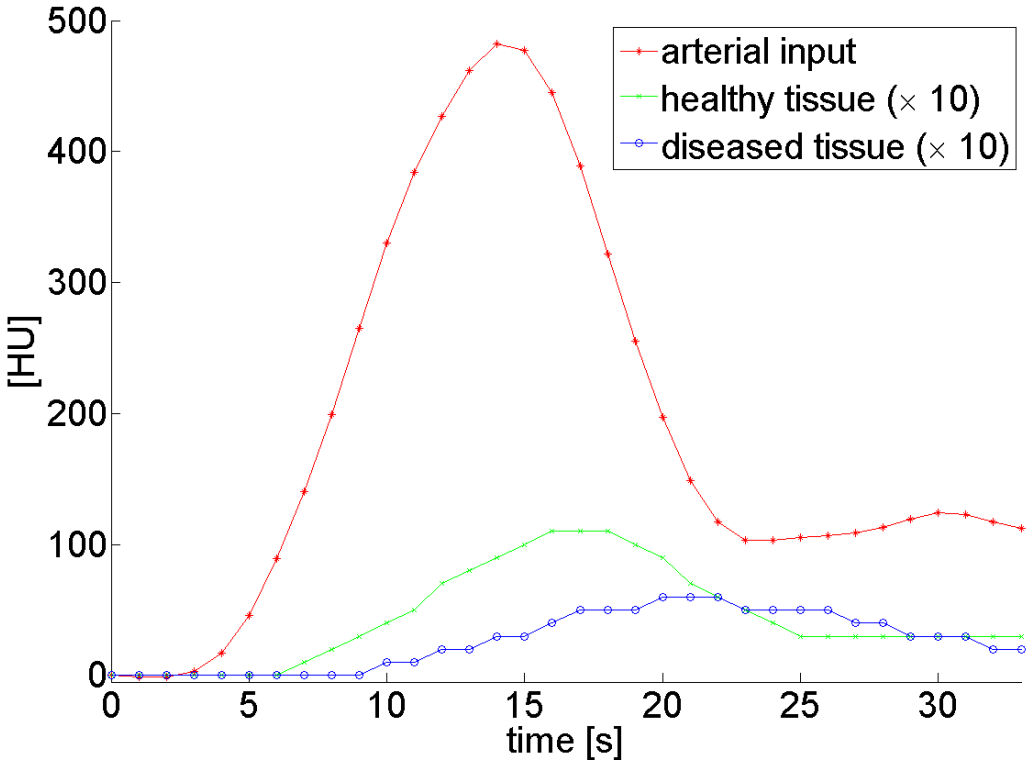

Online available: http://www5.cs.fau.de/data

Dynamic Brain Phantom - Projection Data

Full Projection Data with Tissue and Bone

Subtracted Projection Data with Dynamic Contrast Enhancement

Subtracted Projection Data with Dynamic Contrast Enhancement and Poisson Noise

1. Flat Detector CT Perfusion
2. Digital Brain Perfusion Phantom
3. Reconstruction & Noise Reduction
4. Numerical Study: Digital Brain Phantom
5. Clinical Patient Studies

Flat Detector CT Perfusion

FDK reconstruction of mask and bolus sweeps → Rigid motion correction → Mask subtraction →

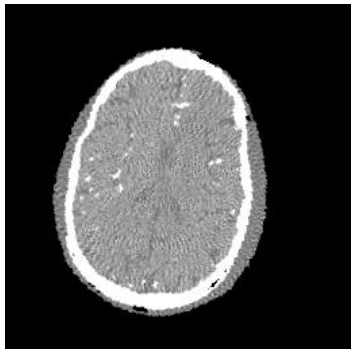

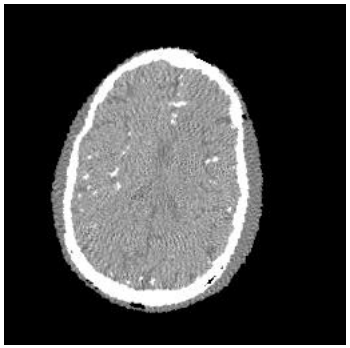

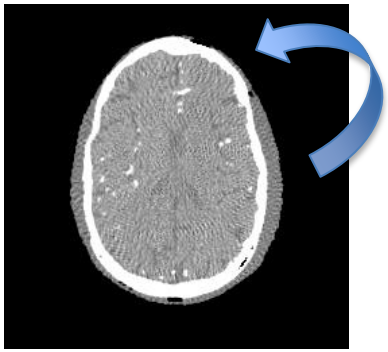

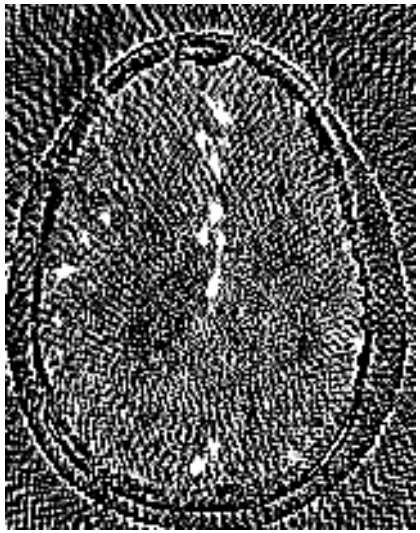

DynaCT Perfusion

Noise & artifact reduction → Time-contrast curve computation → Perfusion parameter maps calculation

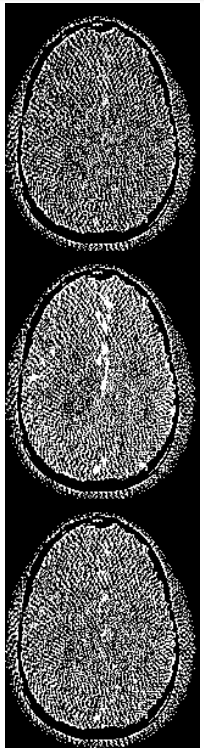

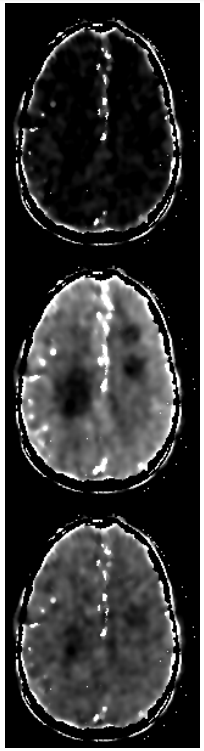

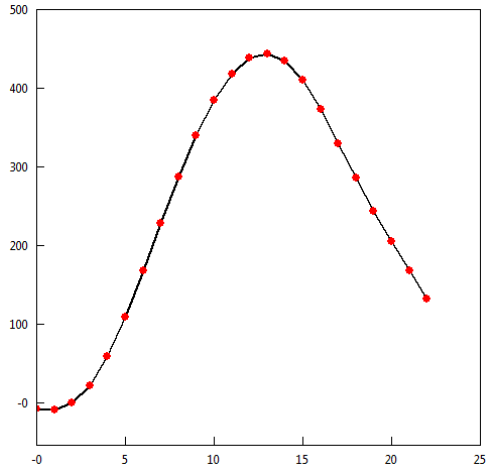



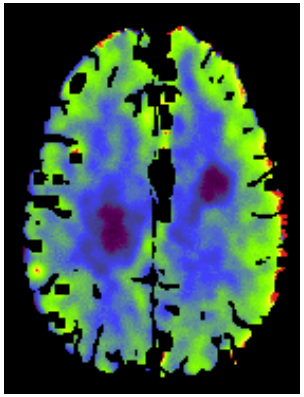

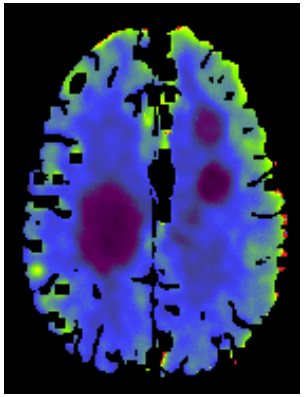

FDK-SR-JBF Algorithm for Flat Detector Perfusion CT

Noise Reduction by Joint Bilateral Filtering (JBF)

Noise Reduction: Bilateral Filtering

I

I'

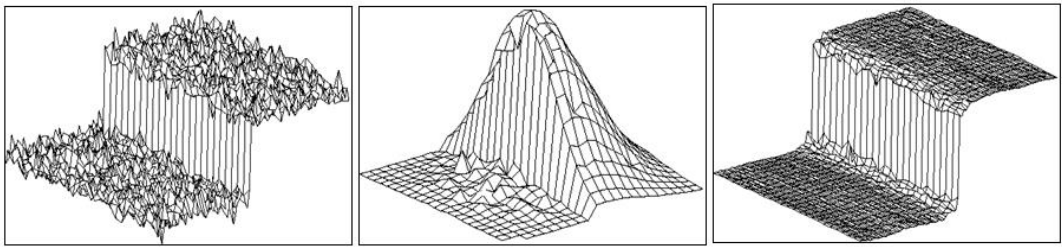

$$I'(\mathbf{p}) = \frac{\sum_{o \in \mathcal{N}_\mathbf{p}} I(\mathbf{p}+\mathbf{o})\mathcal{W}(\mathbf{p},\mathbf{o})}{\sum_{o \in \mathcal{N}_\mathbf{p}} \mathcal{W}(\mathbf{p},\mathbf{o})}$$

$$\mathcal{G}_\sigma(\mathbf{x}) = \exp\left(-0.5 \cdot \|\mathbf{x}\|_2^2 / \sigma^2\right)$$

$$\mathcal{W}(\mathbf{p},\mathbf{o}) = \mathcal{G}_{\sigma_\mathrm{R}}\left(I(\mathbf{p}) - I(\mathbf{p}+\mathbf{o})\right) \cdot \mathcal{G}_{\sigma_\mathrm{D}}(\mathbf{p}-\mathbf{o})$$

Pictures: Tomasi, C & Manduchi, R: *Bilateral Filtering for Gray and Color Images;* Proc. IEEE ICCV, 1998

Noise Reduction: Joint Bilateral Filtering (JBF)

Flash	No Flash	JBF
M	I	I'

$$I'(\mathbf{p}) = \frac{\sum_{o \in \mathcal{N}_\mathbf{p}} I(\mathbf{p}+\mathbf{o}) \mathcal{W}_M(\mathbf{p},\mathbf{o})}{\sum_{o \in \mathcal{N}_\mathbf{p}} \mathcal{W}_M(\mathbf{p},\mathbf{o})} \quad \mathcal{W}_M(\mathbf{p},\mathbf{o}) = \mathcal{G}_{\sigma_\mathrm{R}}\left(M(\mathbf{p}) - M(\mathbf{p}+\mathbf{o})\right) \cdot \mathcal{G}_{\sigma_\mathrm{D}}(\mathbf{p}-\mathbf{o})$$

Pictures: Petschnigg, G et al.: *Digital Photography with Flash and No-Flash Image Pairs;* Proc. ACM SIGGRAPH, 2004

Joint Bilateral Filtering: Perfusion Guidance Volume

Temporal maximum intensity projection (MIP):

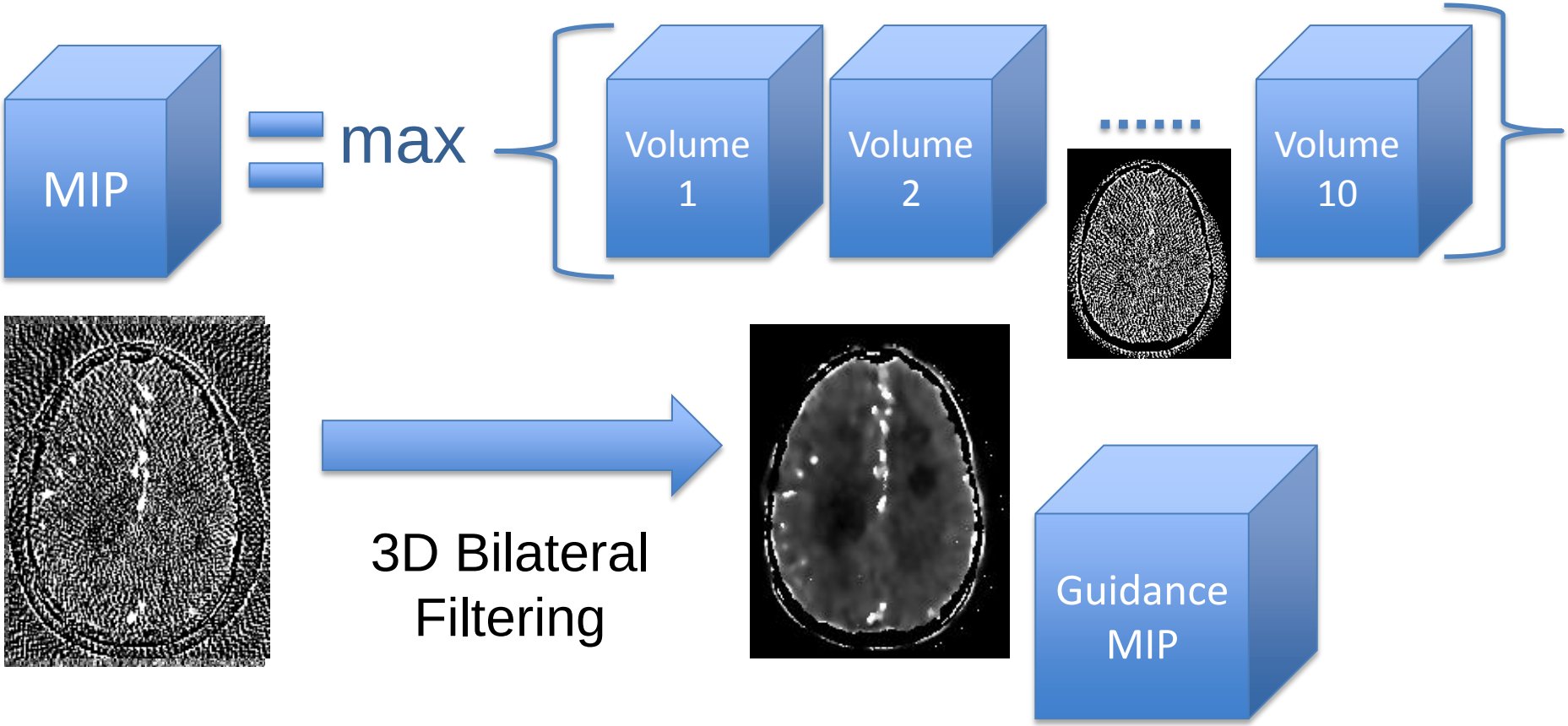

Joint Bilateral Filtering for Flat Detector Perfusion

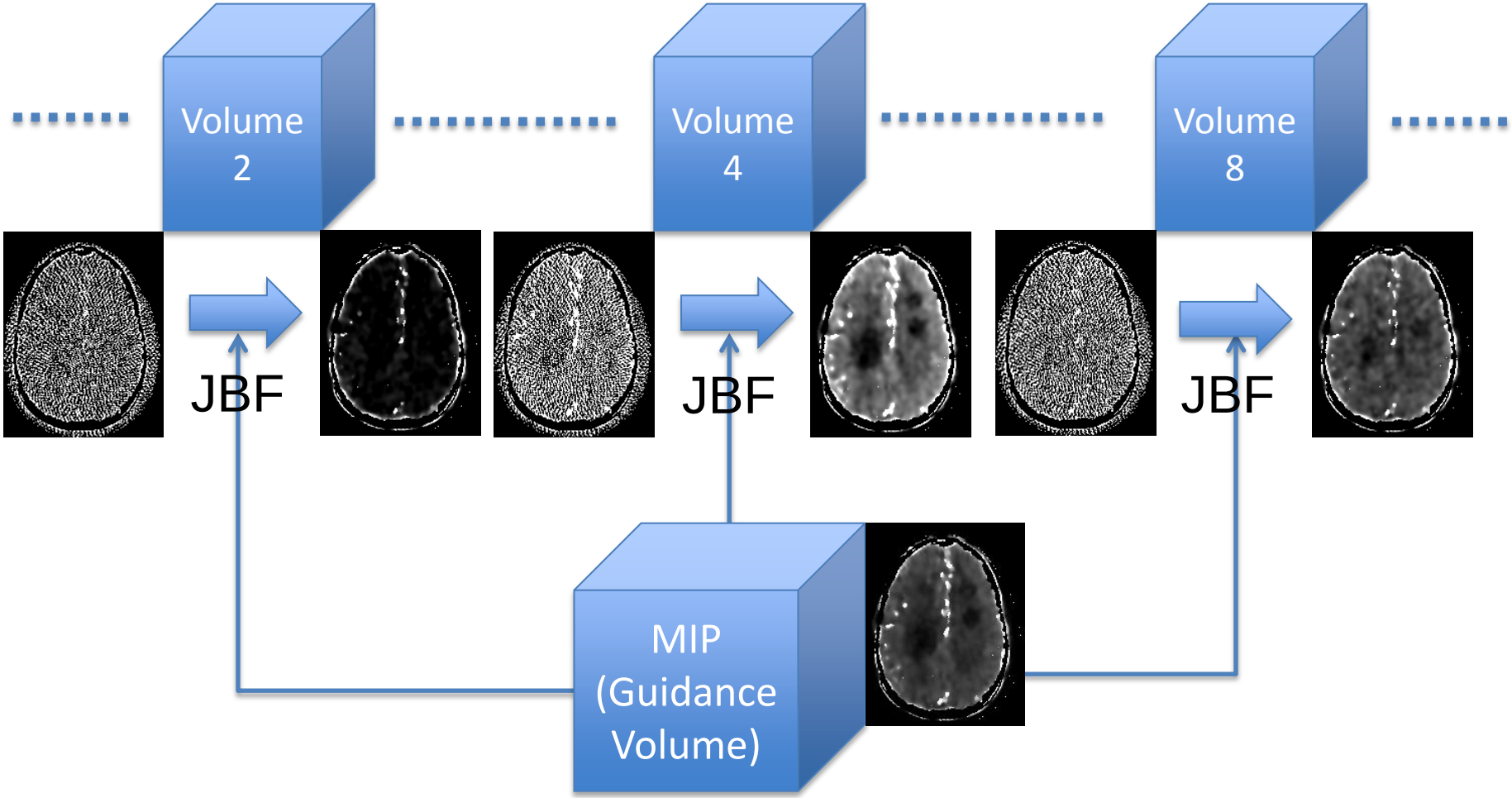

FDK-SR-JBF Algorithm for Flat Detector Perfusion CT

Streak Artifact Reduction (SR)

Streak Artifact Detection in Guidance Image

	Slice 63	Slice 100
MIP		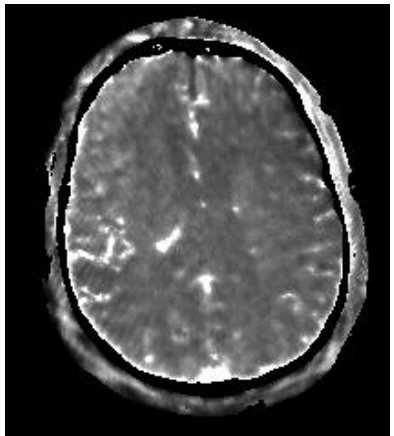
Total Variation of MIP	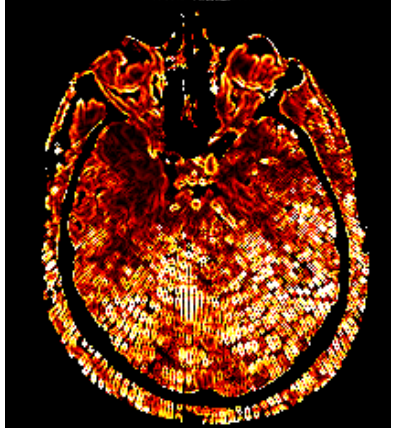	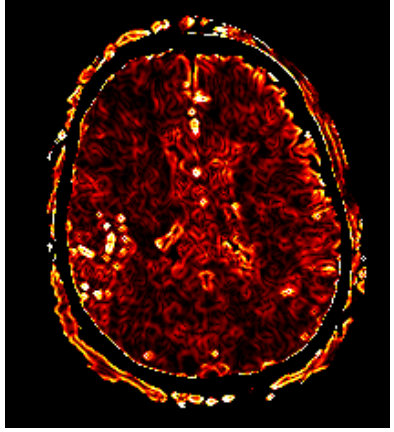

Vessel/Streak Identification

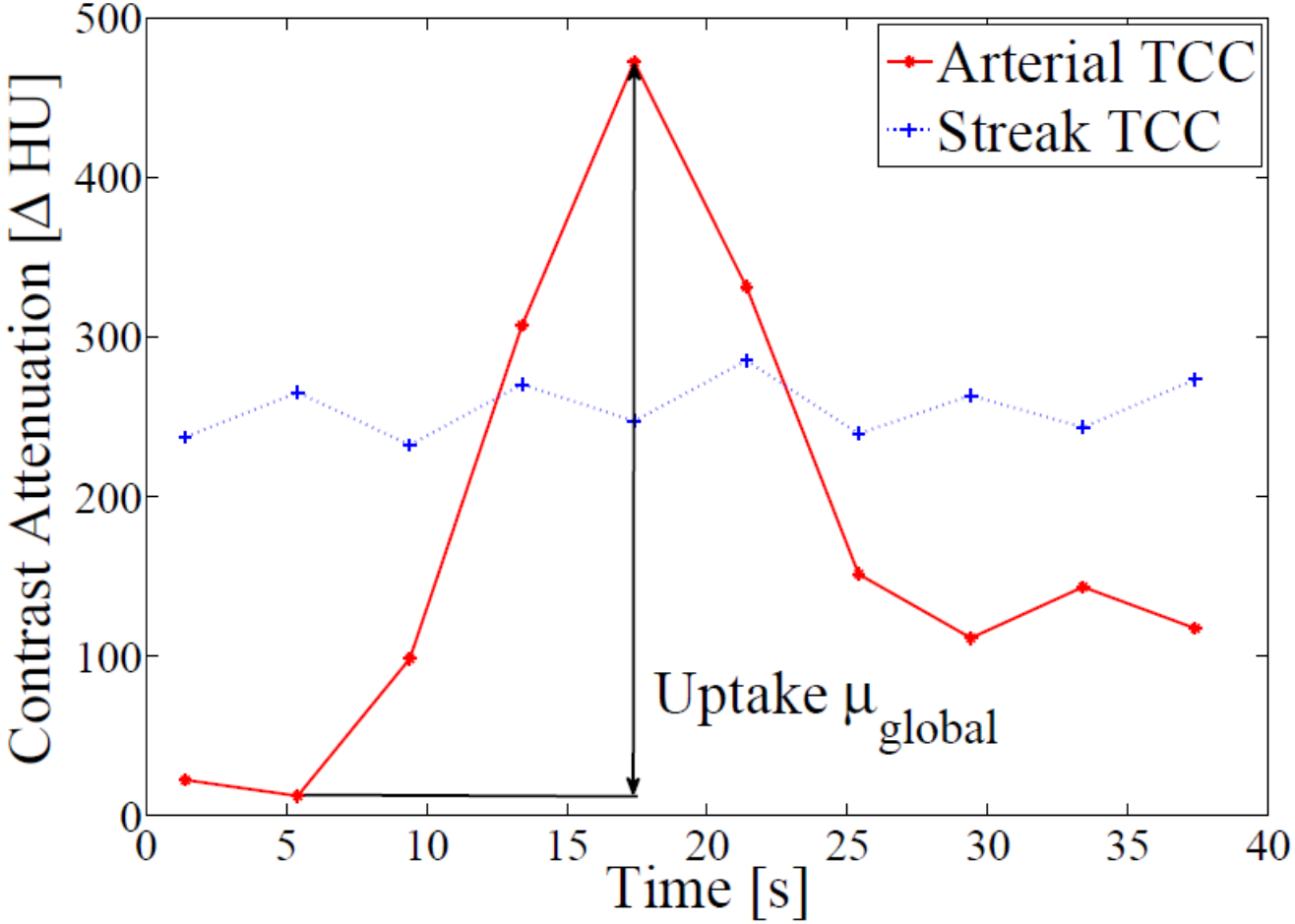

Guidance Image Streak Identification

- Brain segmentation in air, bones and tissue

- Identify vessel & streaks by MIP thresholding and TCC analysis
  - negative MIP value in tissue -> streak
  - high MIP value in tissue:
    - TAC has single high uptake -> vessel
    - Otherwise -> streak

- Identify streaks by total variation of MIP
  - high total variation and no vessel -> streak

Guidance Image Streak Removal (SR)

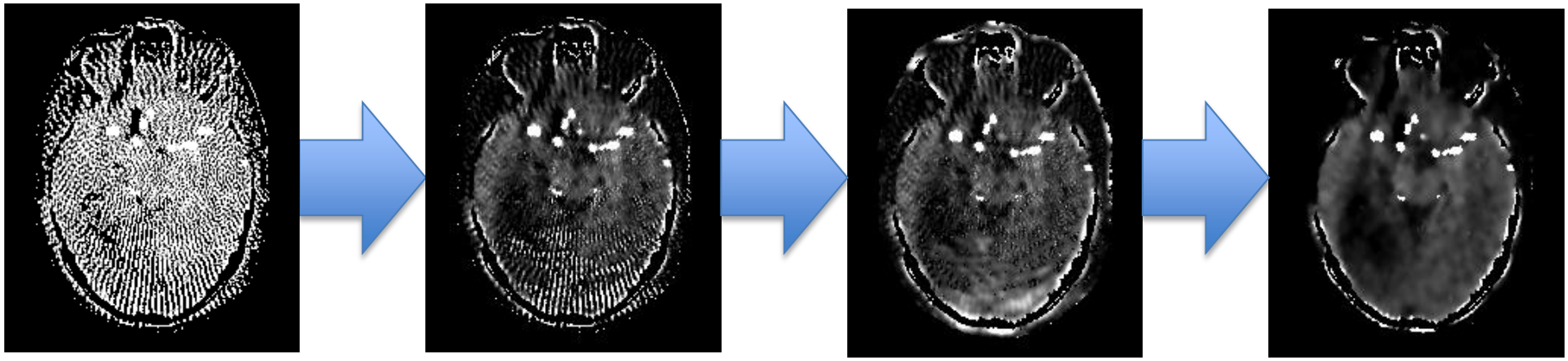

Bilateral filtering

Streak smoothing

Joint bilateral 3 Iterations

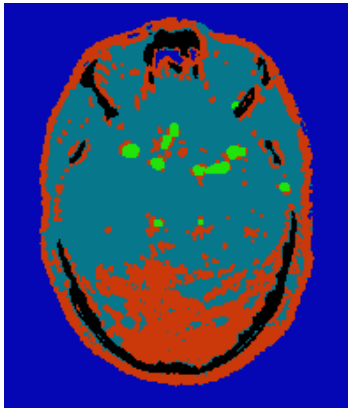

FDK-SR-JBF Algorithm

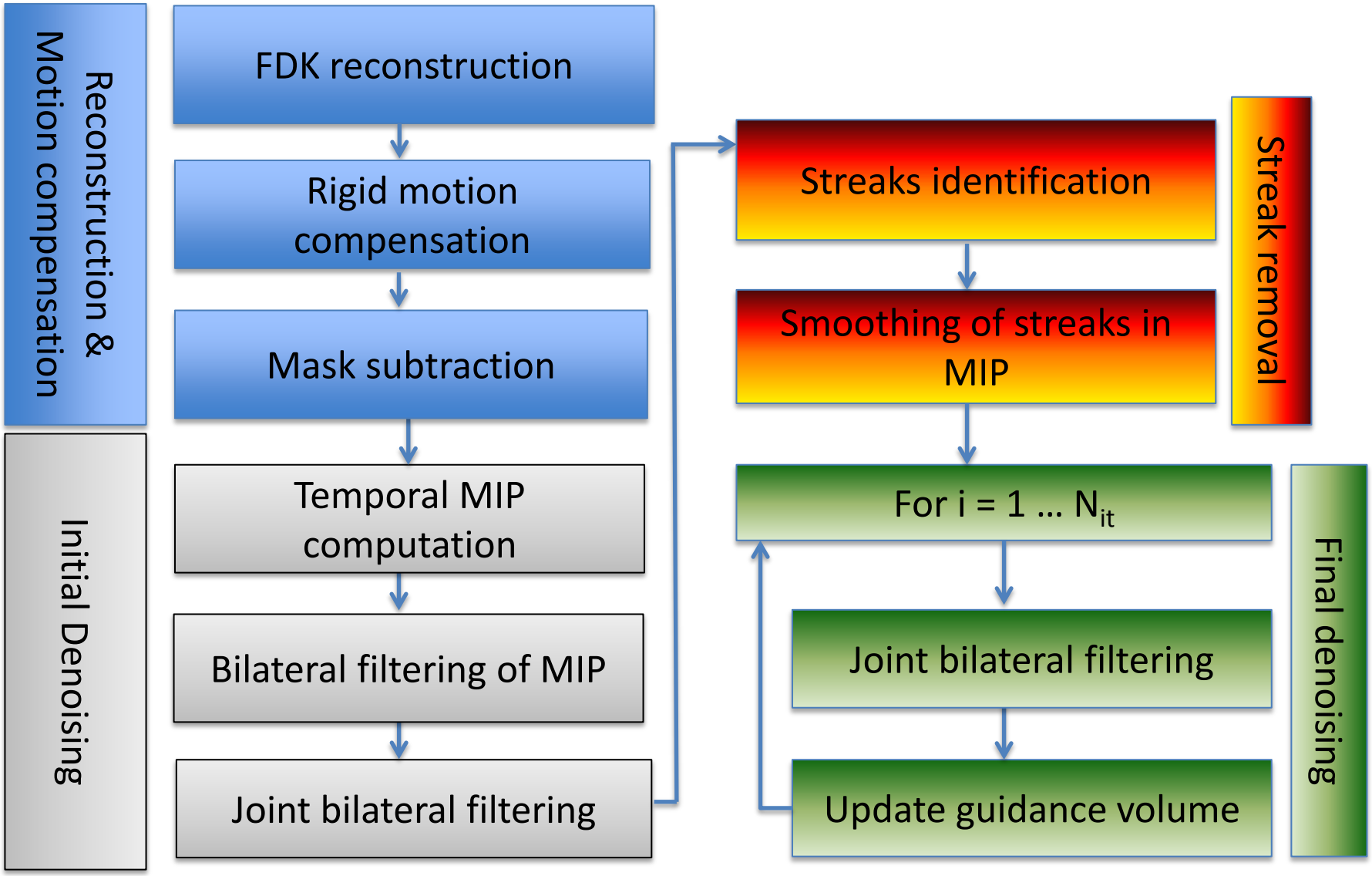

1. Flat Detector CT Perfusion
2. Digital Brain Perfusion Phantom
3. Reconstruction & Noise Reduction
4. Numerical Study: Digital Brain Phantom
5. Clinical Patient Studies

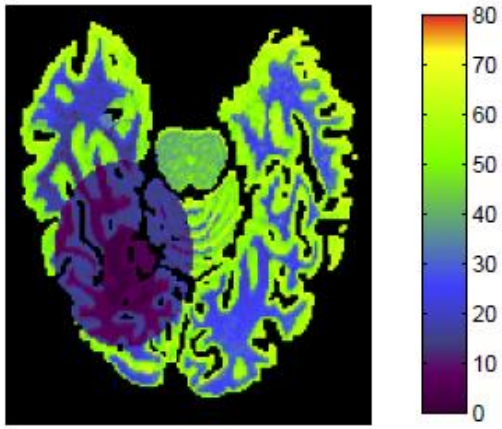

(a) Reference map

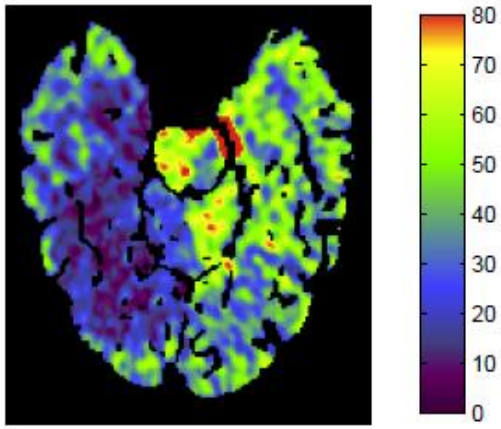

(b) FDK-SMOOTH

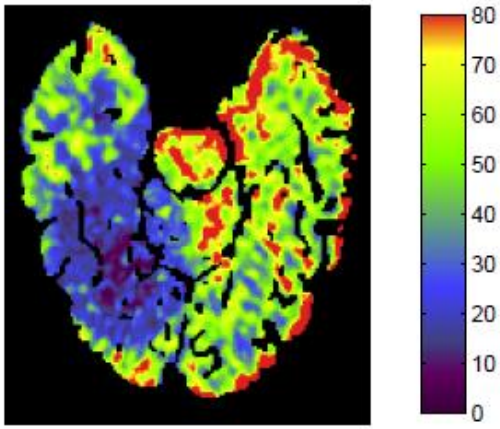

(c) FDK-GAUSS

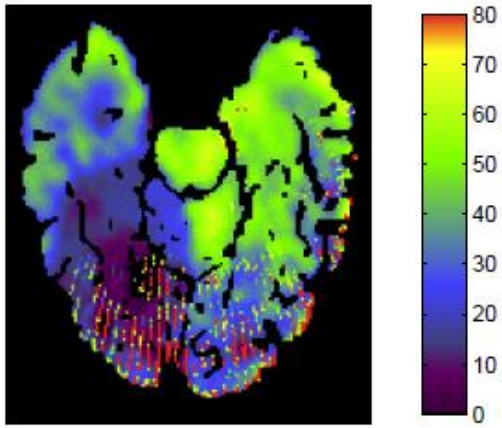

(d) FDK-JBF

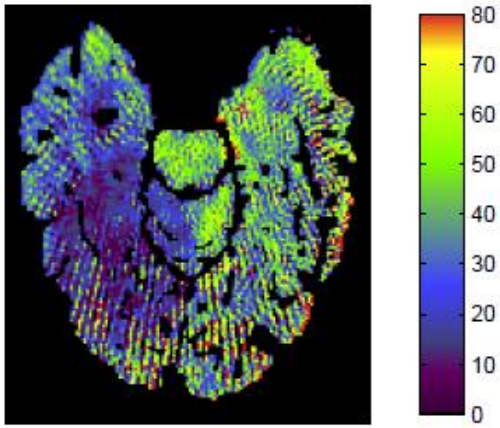

(e) FDK-TIPS-1

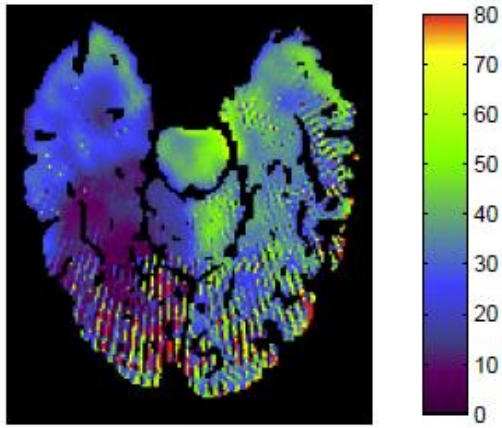

(f) FDK-TIPS-3

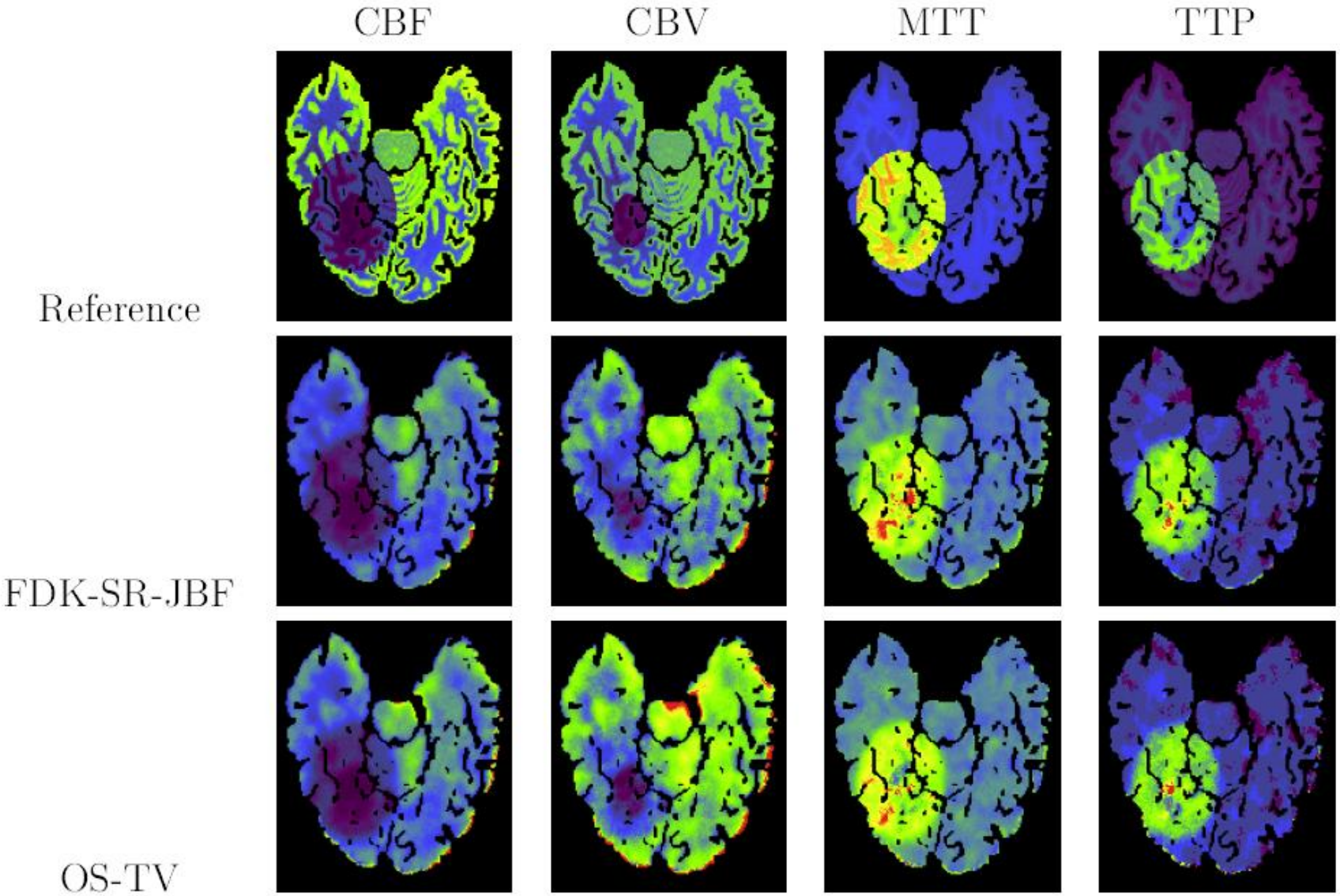
CBF
CBV
MTT
TTP
Reference
FDK-SR-JBF
OS-TV

Digital Brain Phantom - Quantitative Results

	Pearson Correlation		RMSE	
	FDK-SR-JBF	OS-TV	FDK-SR-JBF	OS-TV
CBF	0.83	0.84	7.17 ml/100 g/min	5.94 ml/100 g/min
CBV	0.74	0.75	0.56 ml/100 g	0.85 ml/100 g
MTT	0.85	0.89	2.23 s	2.34 s
TTP	0.87	0.86	1.32 s	1.32 s
Computation Time	69 s	1610 s		

1. Flat Detector CT Perfusion
2. Digital Brain Perfusion Phantom
3. Reconstruction & Noise Reduction
4. Numerical Study: Digital Brain Phantom
5. Clinical Patient Studies

Patient Study with Head Motion
3 s zeego Acquisition

Patient image data by courtesy of Dr. Struffert and Prof. Dörfler, Neuroradiology, Universitätsklinikum Erlangen

- 69 year old male
- Occlusion of the middle cerebral artery on the left
- The cerebral artery could be re-canalized successfully with self-expanding stents

Patient Study with Head Motion

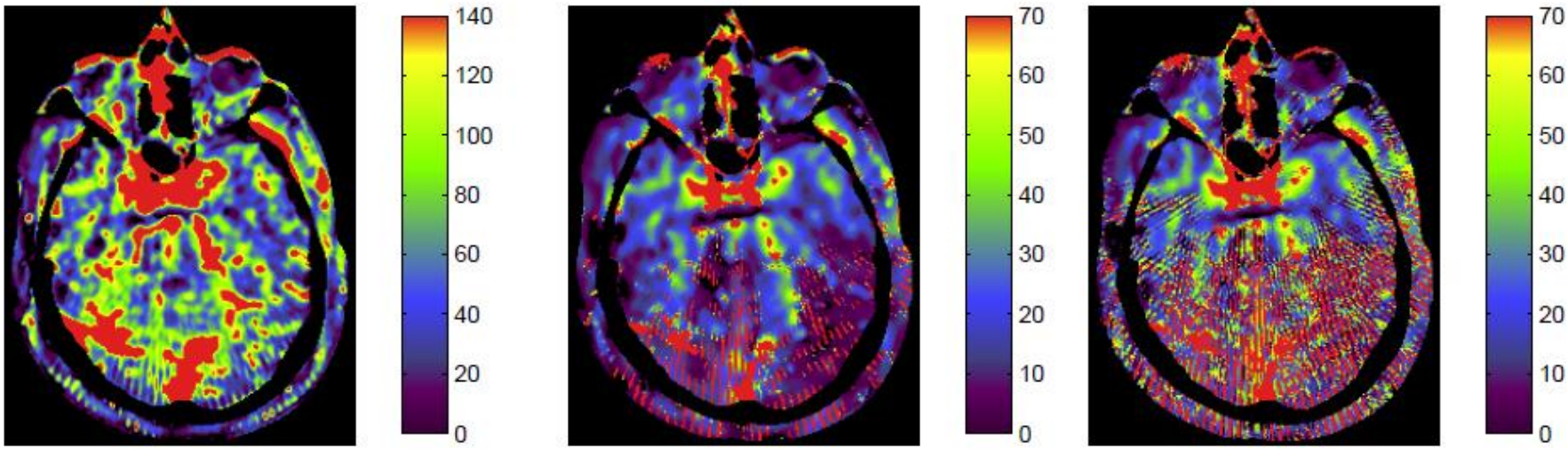

(a) FDK-GAUSS (b) FDK-JBF (c) FDK-TIPS-3

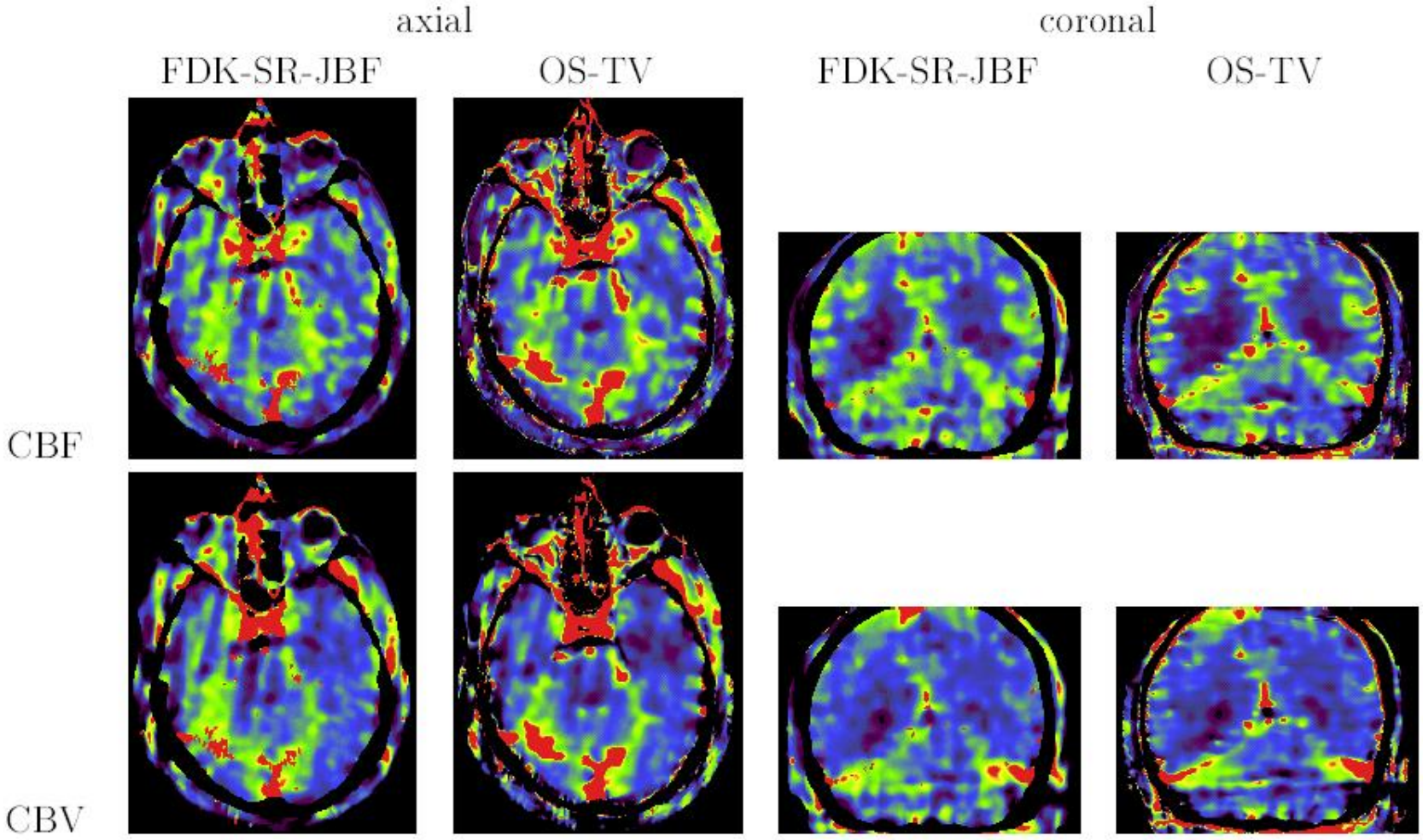
axial
coronal
FDK-SR-JBF
OS-TV
FDK-SR-JBF
OS-TV
CBF
CBV

Patient Study with Pre and Post Treatment Scan 3 s zeego Acquisition

Patient image data by courtesy of Dr. Struffert and Prof. Dörfler, Neuroradiology, Universitätsklinikum Erlangen

- 72 year female patient
- Occlusion left vertebral artery, including the posterior inferior cerebellar artery
- The vertebral artery could be re-canalized successfully by mechanical recanalization therapy

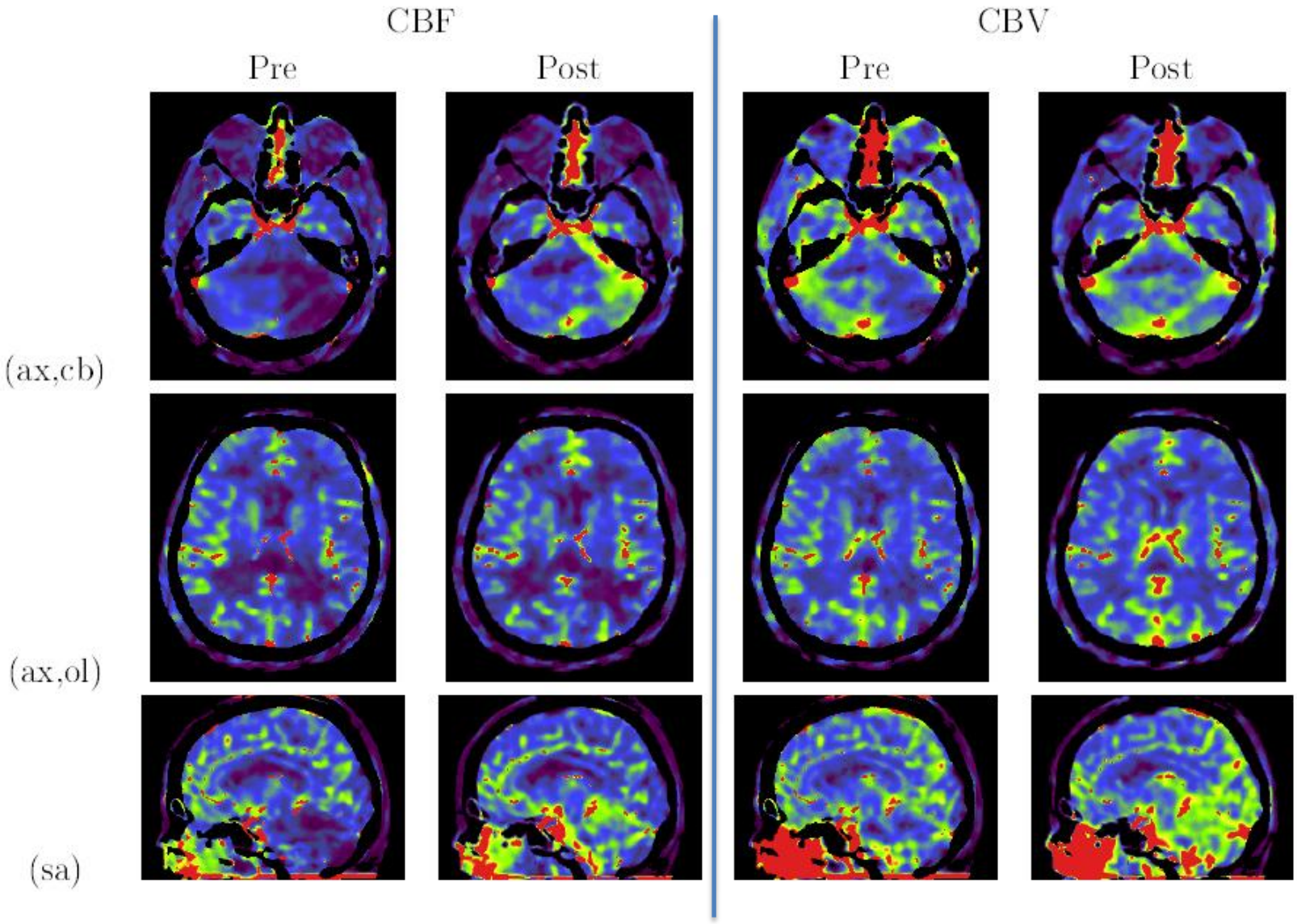
CBF
CBV
Pre
Post
Pre
Post
(ax,cb)
(ax,ol)
(sa)

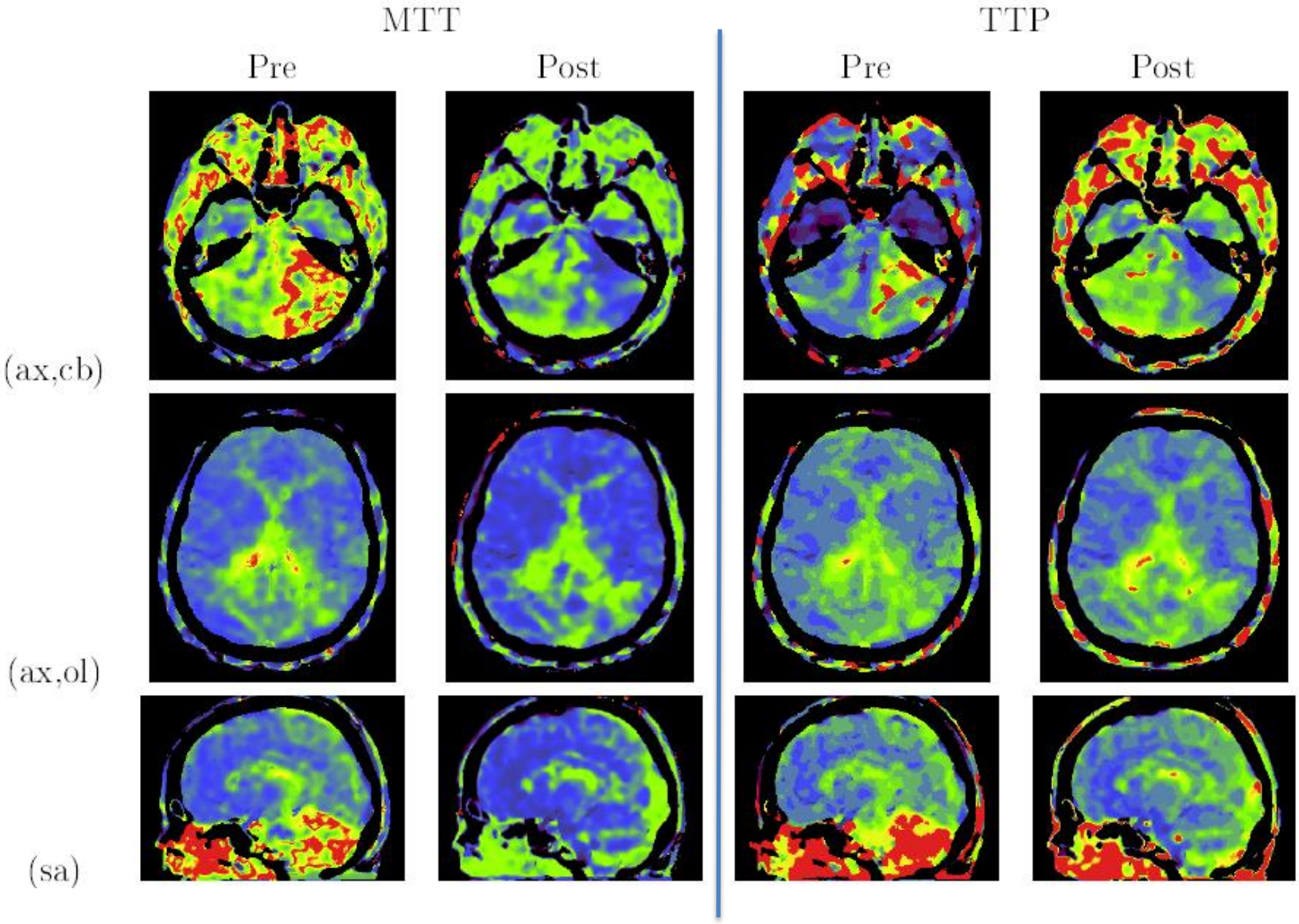
MTT
TTP
Pre
Post
Pre
Post
(ax,cb)
(ax,ol)
(sa)

Patient Study with Pre and Post Treatment Scan 5 s bi-plane Acquisition

Patient image data by courtesy of Dr. Struffert and Prof. Dörfler, Neuroradiology, Universitätsklinikum Erlangen

- 87 year female patient
- Occlusion of the right distal carotid artery
- The carotid artery could be recanalized successfully by mechanical recanalization therapy

Flat Detector CT CBF & CBV Maps

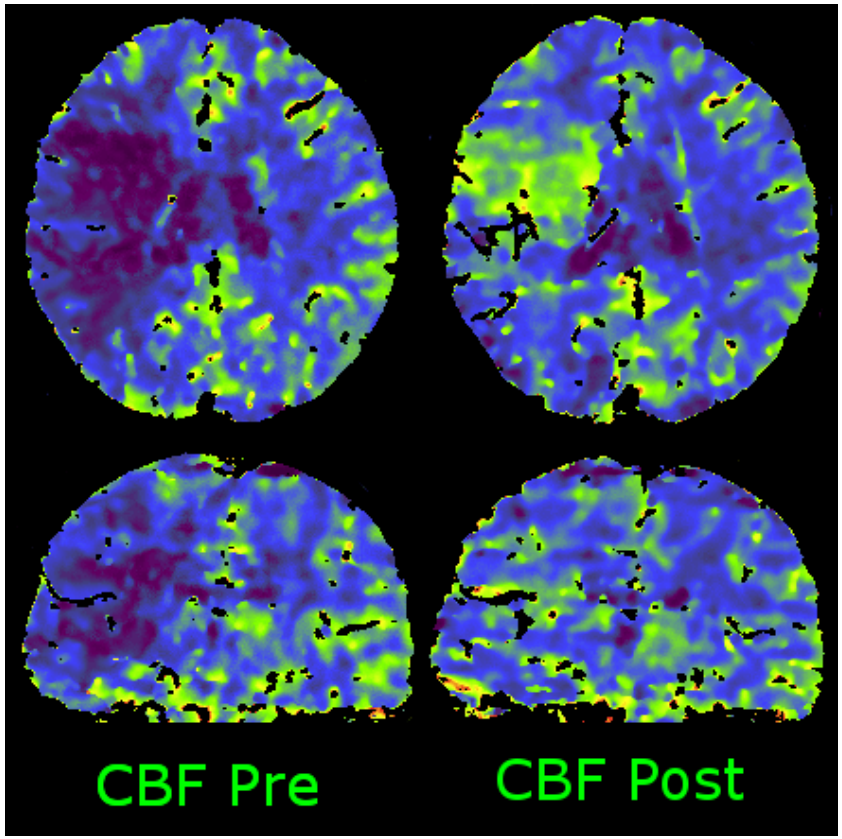

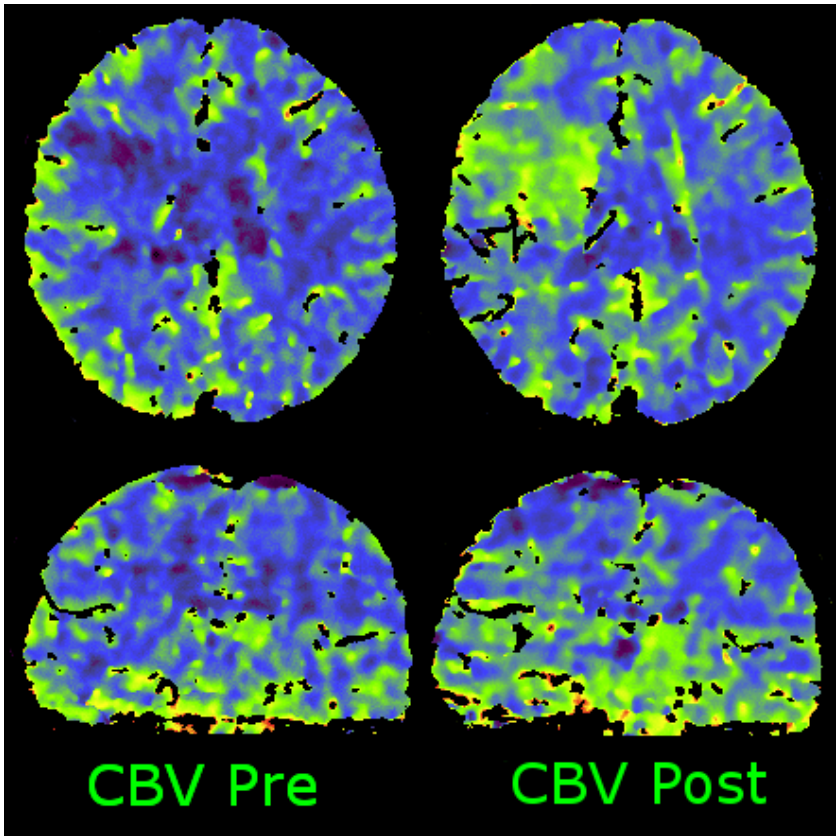

Flat Detector CT MTT & TTP Maps

Pre Treatment | Post Treatment

MTT

TTP

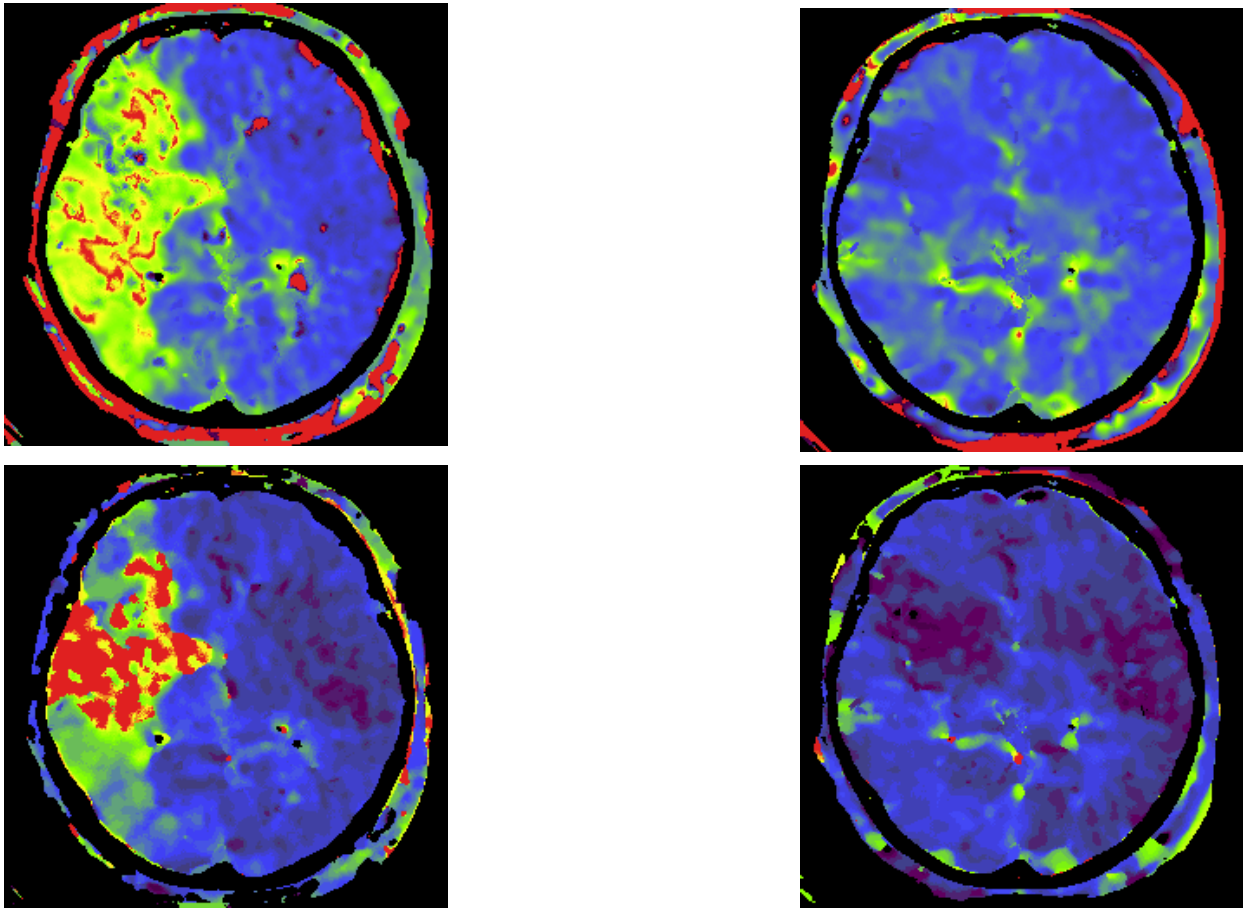

Dynamic Angiography

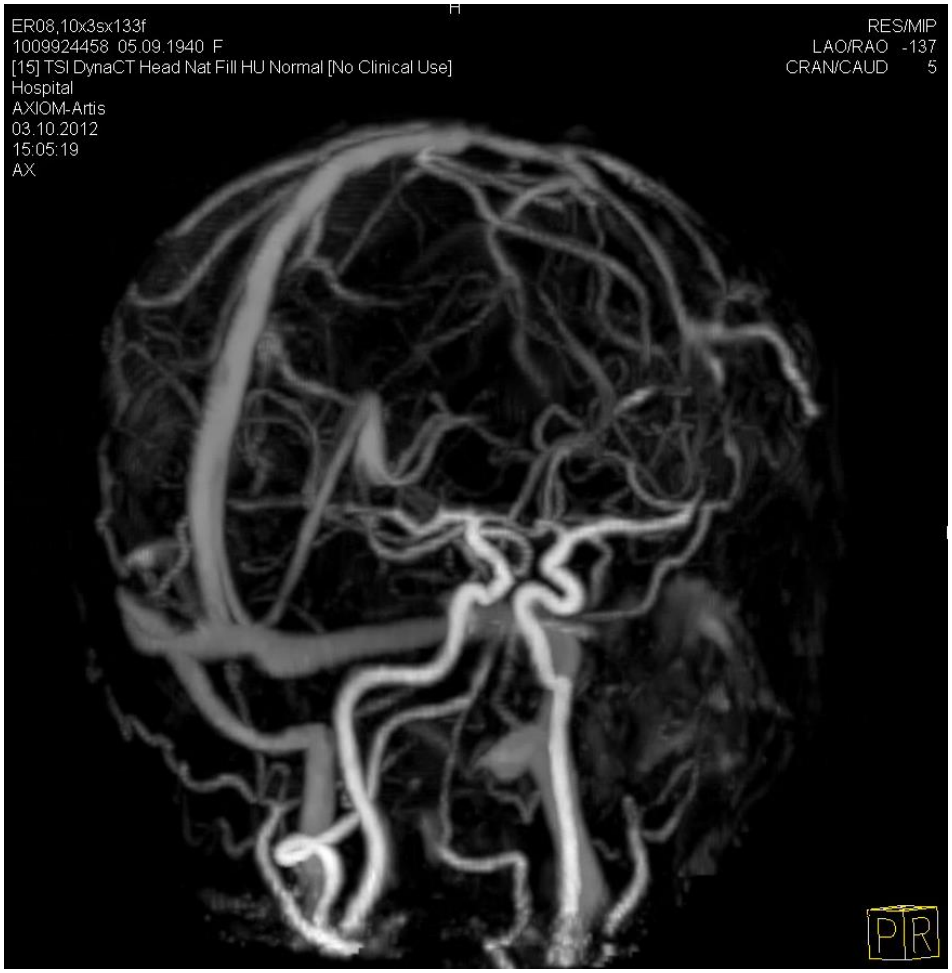

Summary & Outlook

- Interventional perfusion imaging with flat detector CT in clinical practice is feasible

- FDK-SR-JBF approach for computational fast noise and streak artifact reduction

- Outlook:
  - Improved streak identification using pattern recognition approaches
  - Online motion correction
  - Advanced analytic reconstruction
  - Further validation with patient studies