LEHRSTUHL FÜR MUSTERERKENNUNG
PATTERN RECOGNITION LAB

FRIEDRICH-ALEXANDER UNIVERSITÄT ERLANGEN-NÜRNBERG
FACULTY OF ENGINEERING

Patch-based Carcinoma Detection on Confocal Laser Endomicroscopy Images - A Cross-Site Robustness Assessment

Marc Aubreville, Miguel Goncalves, Christian Knipfer, Nicolai Oetter, Tobias Würfl, Helmut Neumann, Florian Stelzle, Christopher Bohr, and Andreas Maier

BIOIMAGING 2018, Funchal, Madeira, Portugal, Jan 20, 2018

in cooperation with:

FRIEDRICH-ALEXANDER UNIVERSITÄT ERLANGEN-NÜRNBERG
MEDIZINISCHE FAKULTÄT

Universitätsklinikum Erlangen

UKE HAMBURG

JG|U

SAOT
erlangen graduate school in advanced optical technologies

Squamous Cell Carcinoma (SCC)

- Common kind of cancer of the epithelium
- Approx. 1.2M cases each year
  (Forastiere et al., 2001; Ferlay et al., 2014)
- Head and Neck SCC occurs e.g. in:
  - Oral Cavity
  - Vocal Cords
- Often diagnosed at late stage
  - Reduced treatment outcomes
  - Increased mortality (Muto et al., 2004)

Oral Cavity SCC

[Oetter et al., 2016]

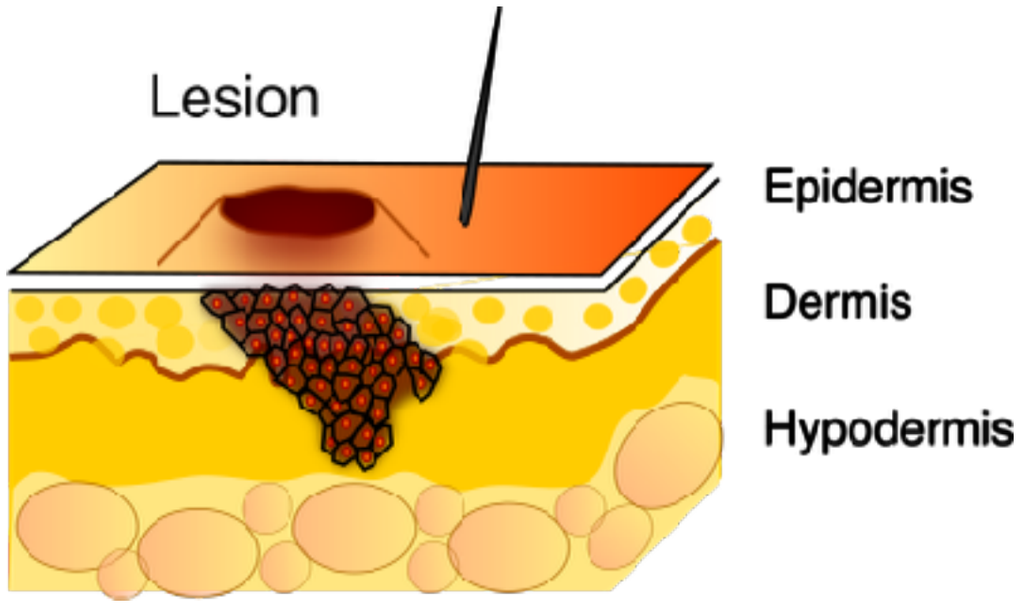

Diagnosis of Head and Neck Squamous Cell Carcinoma

- Diagnosis (gold standard) is performed using histopathology
- Invasive, carries risks of infections and bleeding
- Problematic for intra-operative use
  - Limited sample size (Nathan et al., 2014)
  - Frozen samples —> Reduced quality
  - Associated with high stress level and effort (Agaimy et al., 2012)

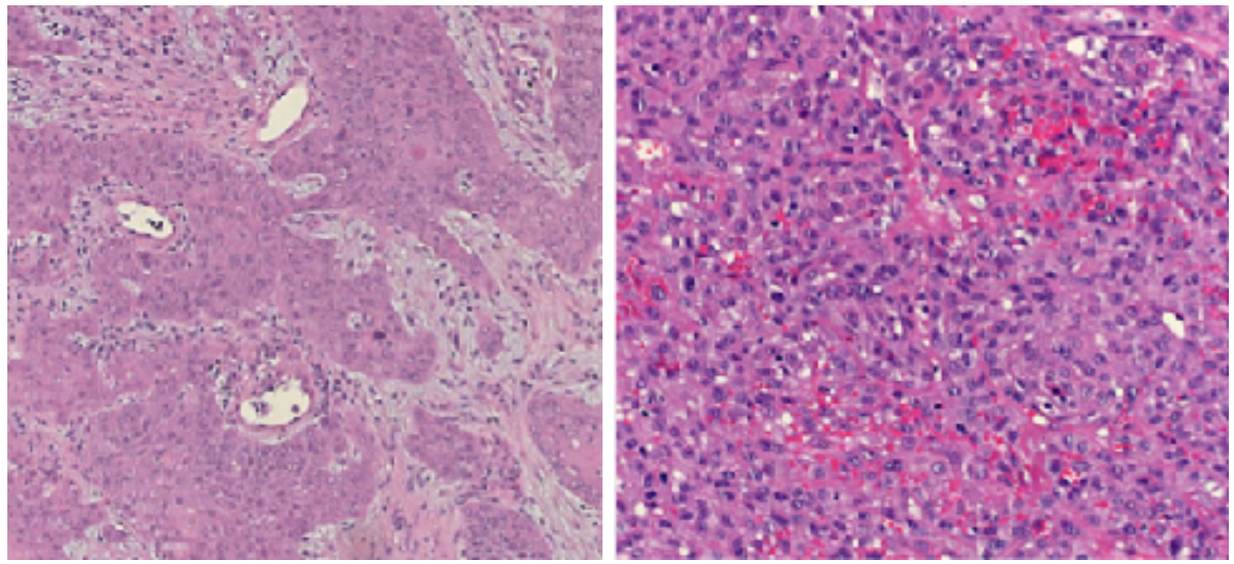

[Oetter et al., 2016]

Confocal Laser Endomicroscopy

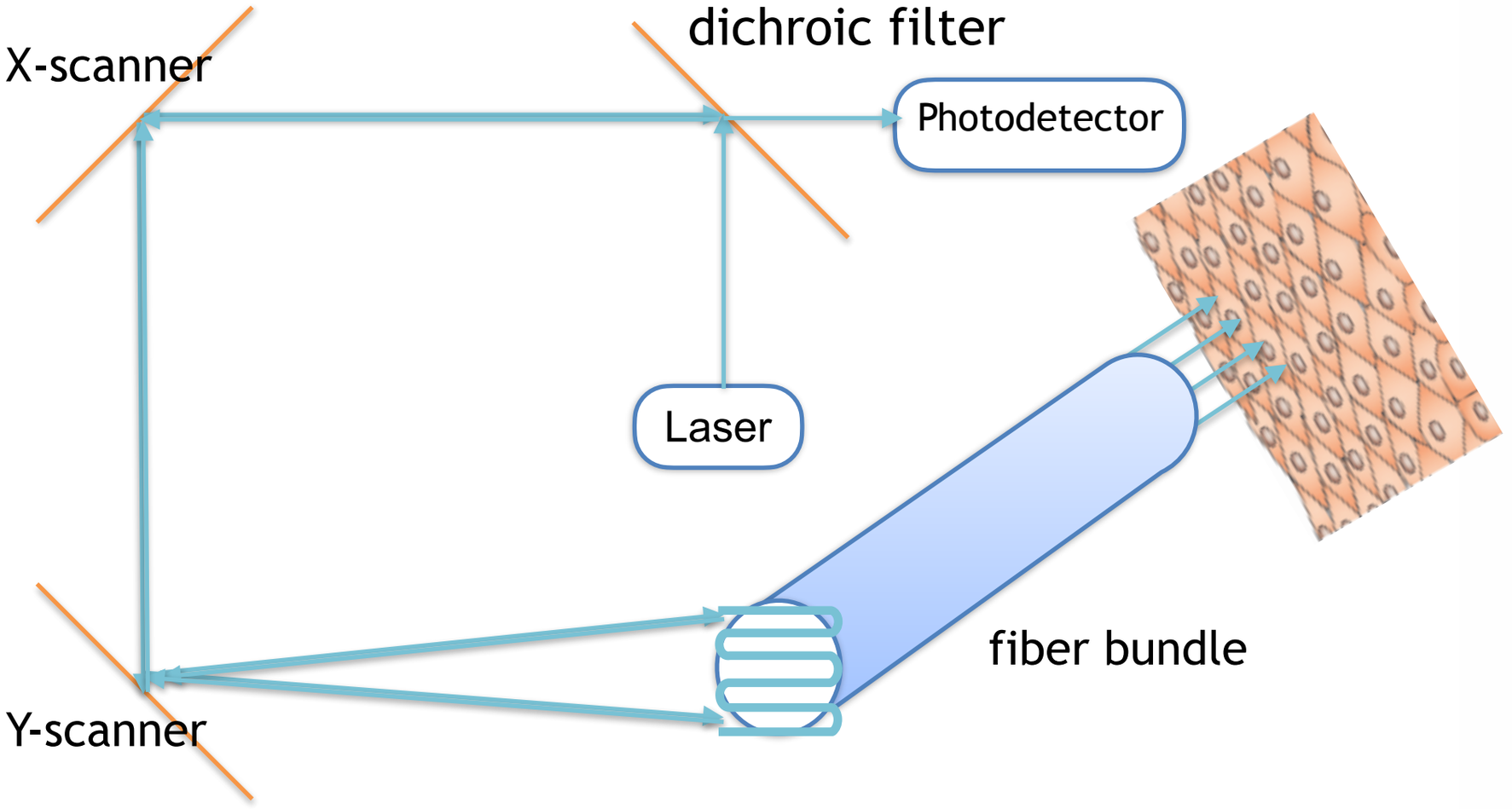

[Laemmel et al 2004]

[Cellvizio, Mauna Kea Technologies]

Impairments and Artifacts

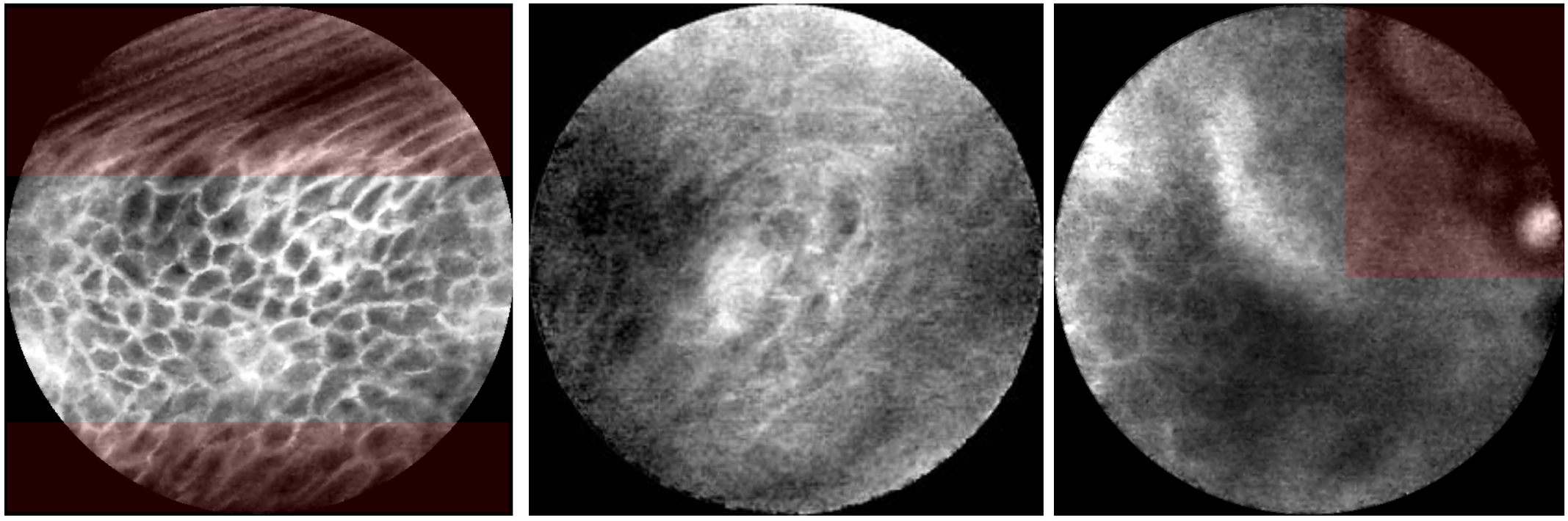

Motion Artifacts Noisy Images Optical Artifacts

—> Not all image parts should be used for classification.

Our data set

- Oral Cavity (OC) data set:
  - N=12 patients, all with squamous cell carcinoma
  - Recorded 3 defined locations plus lesion site.

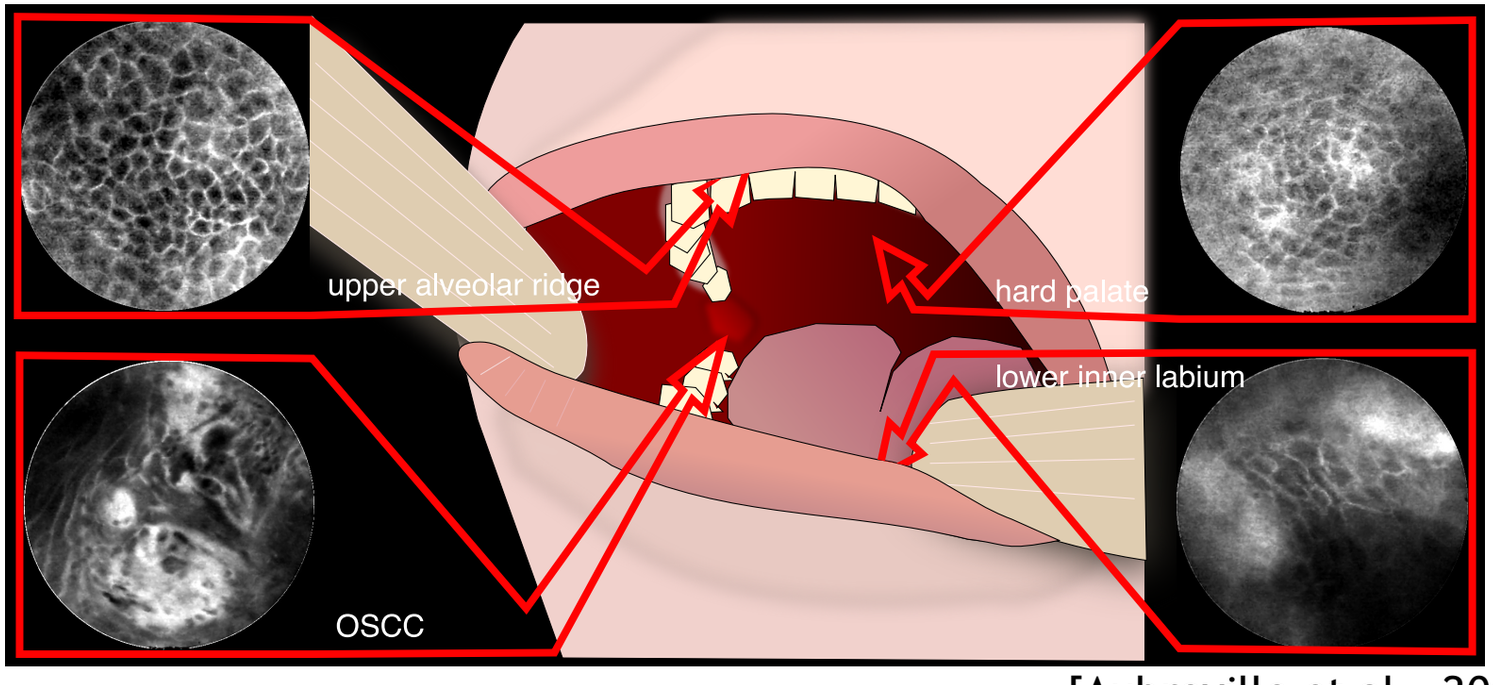

[Aubreville et al., 2017]

CLE images of epithelial tissue of the oral cavity

clinically normal oral cavity images

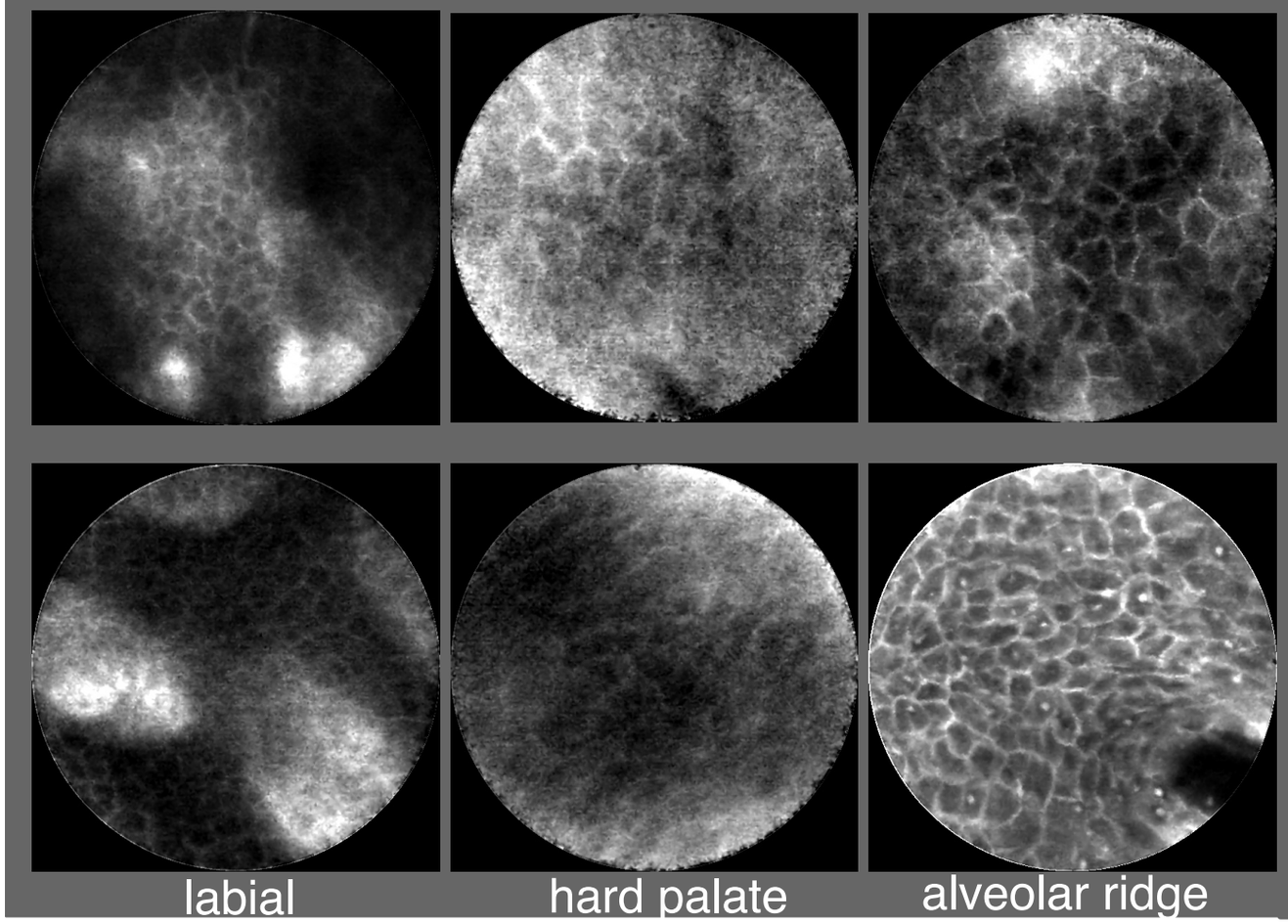

verified carcinoma

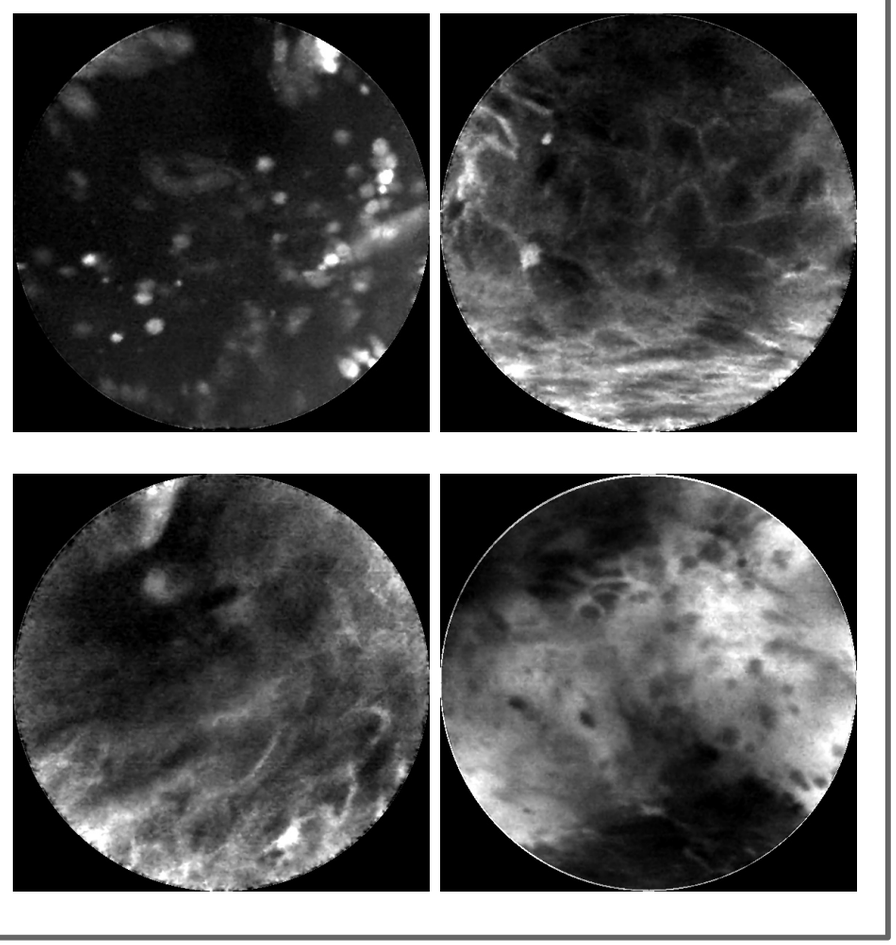

Preprocessing [Aubreville et al.,2017]

- Patch extraction:
  - Coverage of large parts of the overall image
  - Reduction of network capacity to reduce overfitting



- Downscaling
  - Reduction of computational complexity
  - Reduction of noise

All code available: www5.cs.fau.de/~aubreville

Patch Classification [Aubreville et al.,2017]

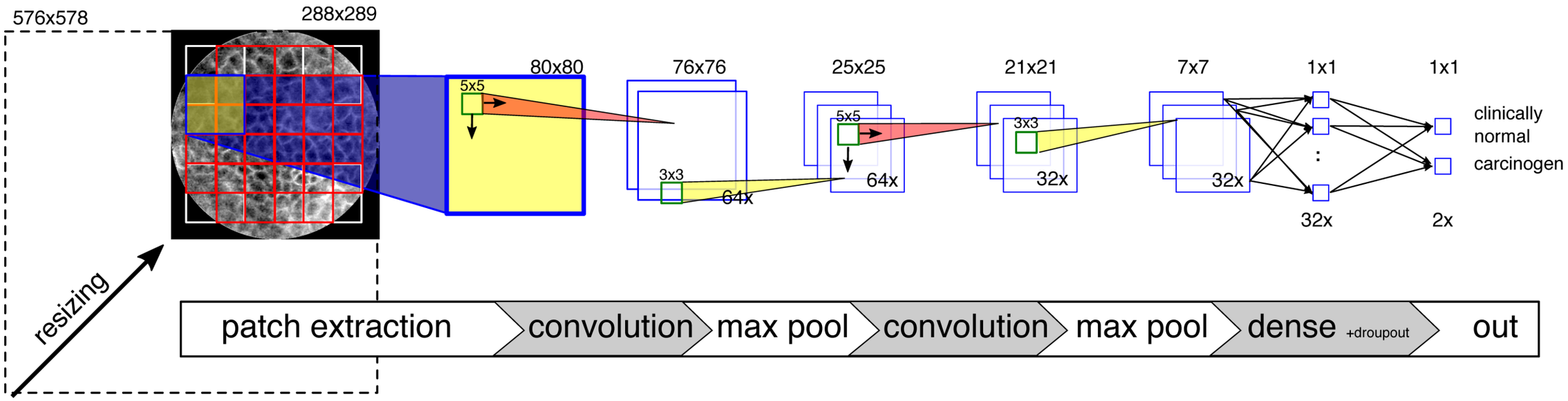

- Used image labels as patch labels
- NN trained from scratch, optimized with cross-entropy / ADAM optimizer

Patch Probability Fusion [Aubreville et al.,2017]

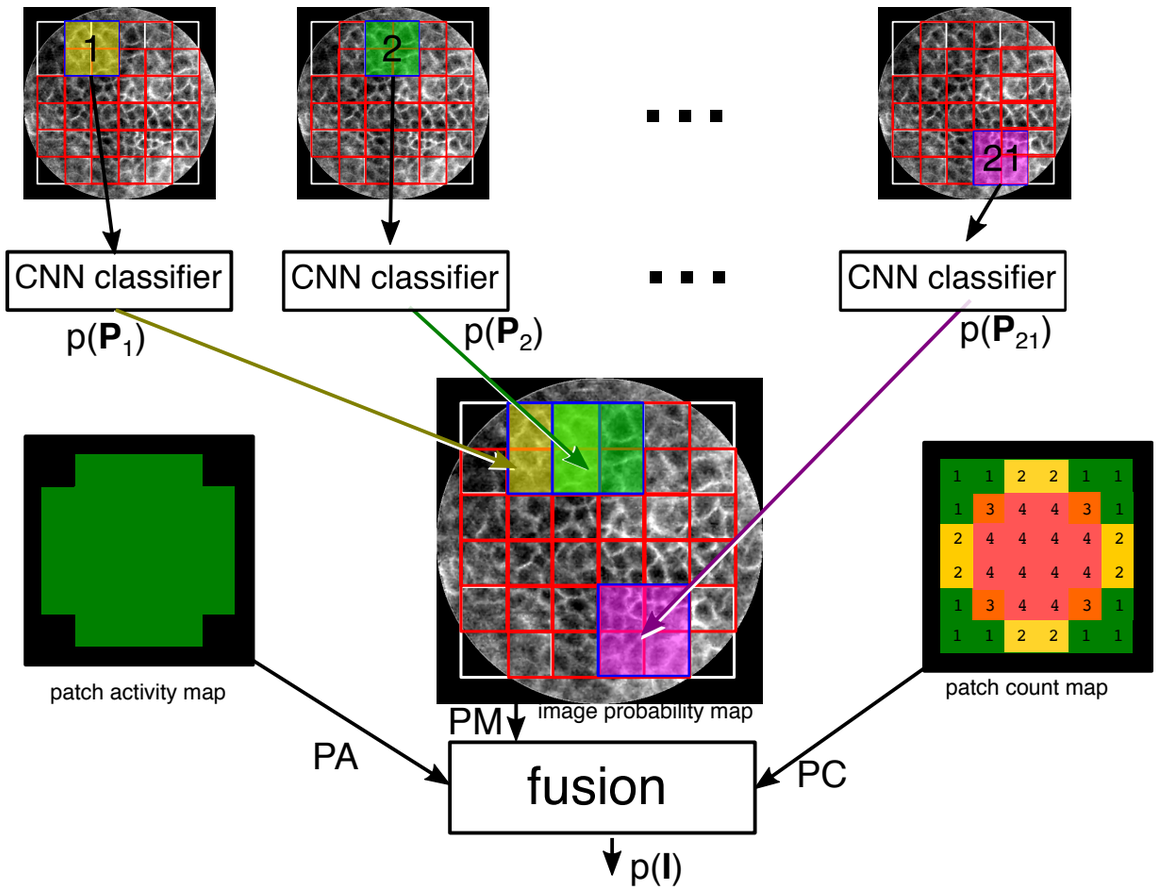

$$A_{x,y}(\mathbf{P}_i) = \begin{cases} 1 & \text{if } (x, y) \in [c_1, c_2] \times [c_3, c_4] \\ 0 & \text{else} \end{cases}$$

$$\mathrm{PA}_{x,y} = \left(\sum_i A_{x,y}(\mathbf{P}_i) \right) \geq 1$$

$$\mathrm{PC}_{x,y} = max\left(1, \sum_i A_{x,y}(\mathbf{P}_i)\right)$$

$$\mathrm{PM}_{x,y} = \mathrm{PA}_{x,y} \cdot \mathrm{PC}_{x,y}^{-1} \cdot \sum A_{x,y}(\mathbf{P}_i) \cdot p(\mathbf{P}_i)$$

$$p(\mathbf{I}) = \left(\sum_{x,y} \mathrm{PA}_{x,y} \right)^{-1} \sum_{x,y} \mathrm{PM}_{x,y}$$

Optimization of Rescaling

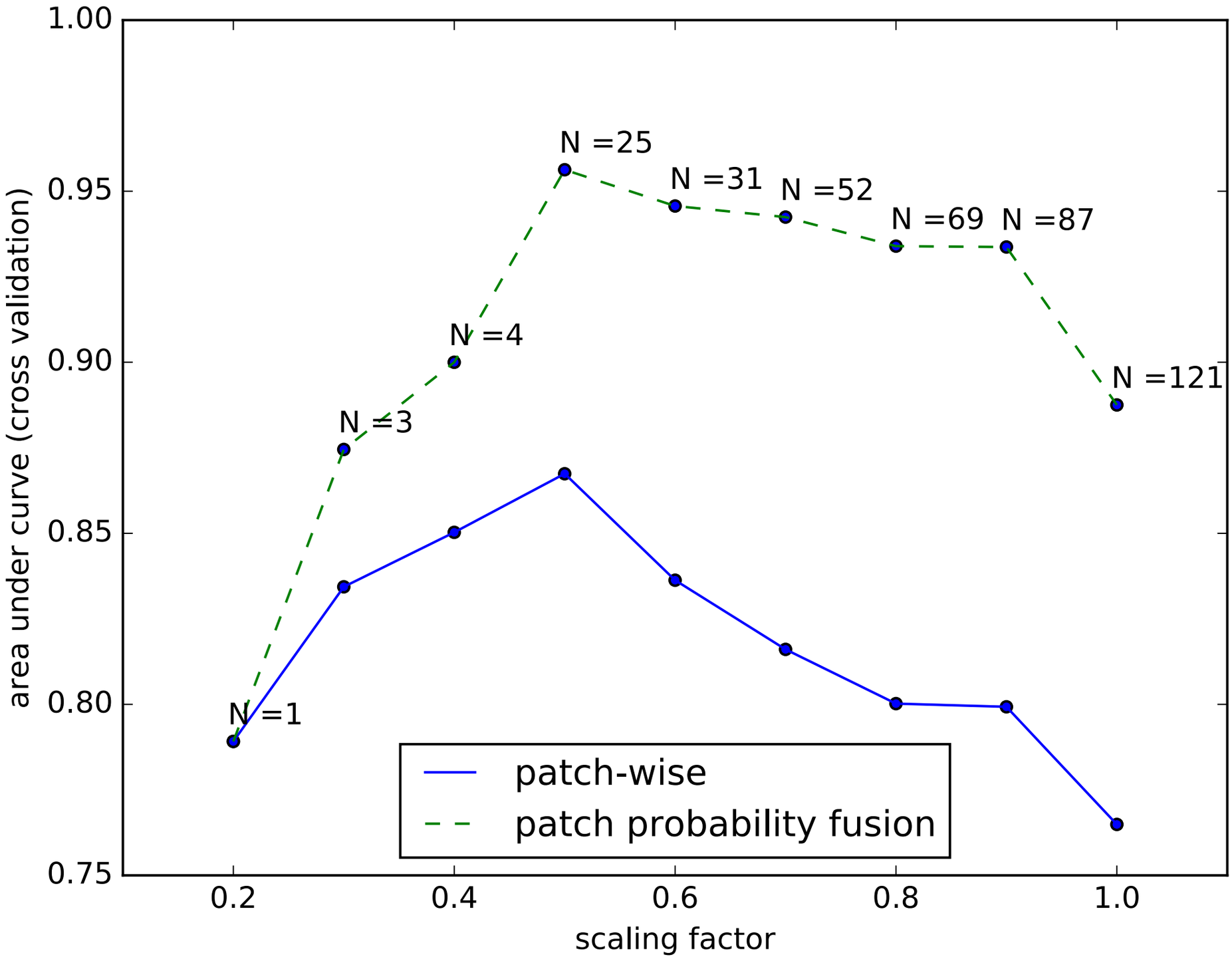

Transfer Learning Approach

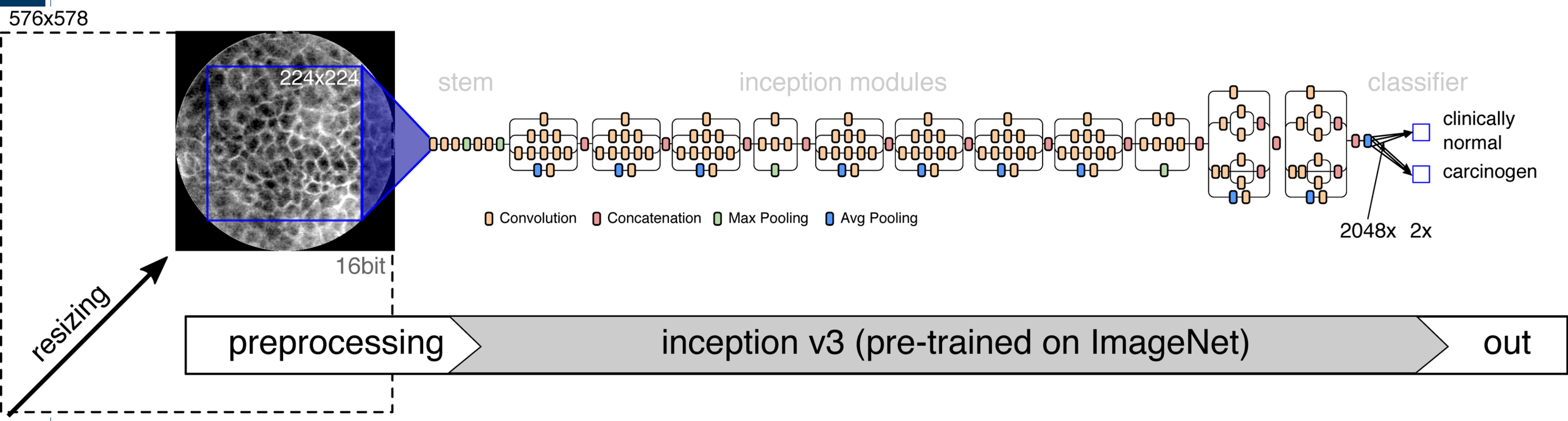

- Backpropagation only on dense layers
- Approach is discarding image information

LOPO Cross-Validation Results

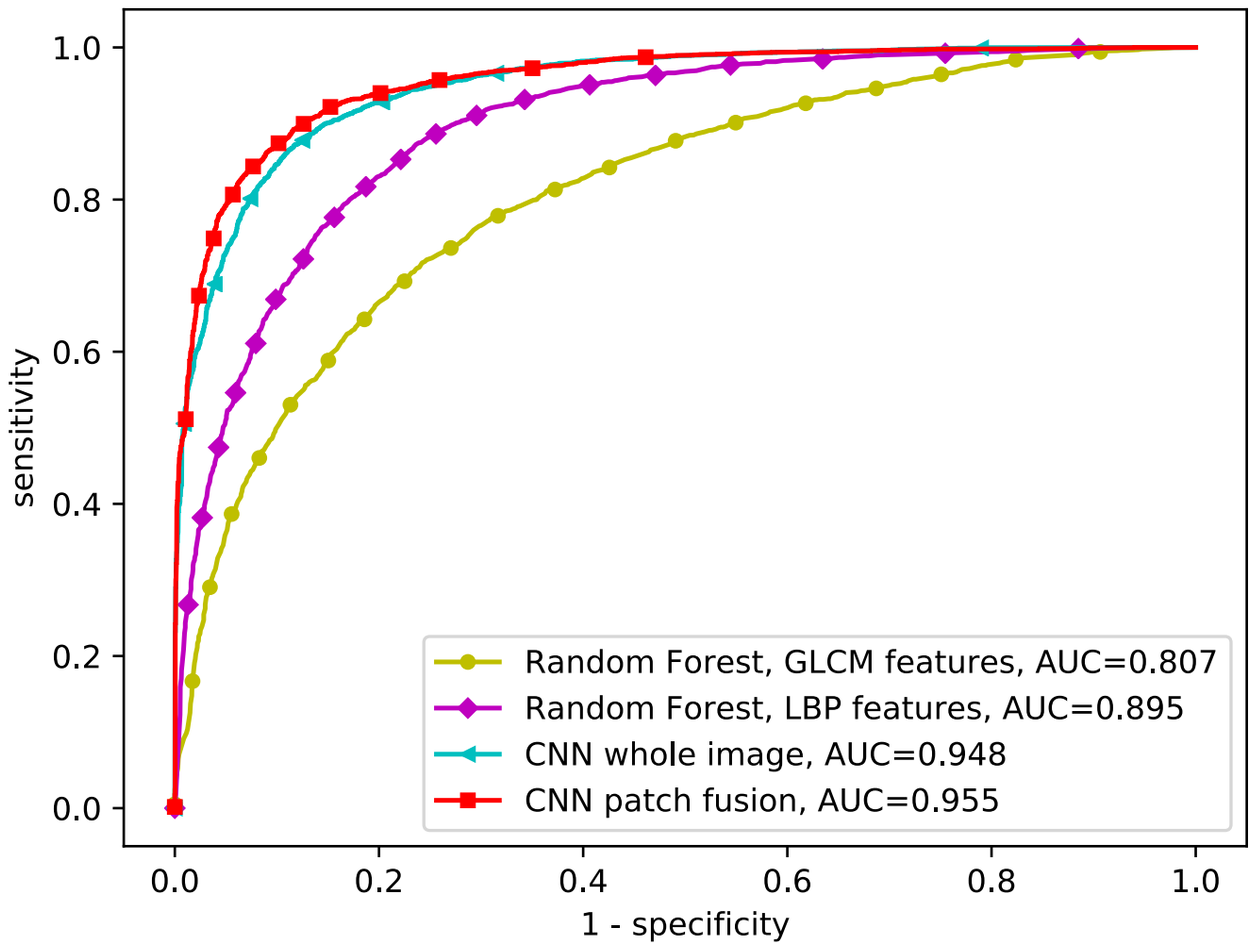

[Aubreville et al., 2017]

Generalization

Method generalization	Data generalization
Does the method work well on other similar data?	Does the classifier trained on our data set work on other data sets?

Test on:
Different data set, from different clinic, from different anatomy.

Squamous Cell Carcinoma (SCC) of the vocal folds

- SCC is the most prevalent form of cancer of the vocal tract (Parkin et al., 2015)
- Bright light endoscopy insufficient (high range of benign alterations) (Goncalves et al., 2017)
- Tiny structures, yet biopsies require sufficient amount of material.
- Extensive biopsy causes functional problems (Cikojevic´ et al., 2008)
  - chronic hoarseness
  - other voice modifications

Non-invasive diagnostic tool would significantly increase life quality

CLE images of epithelial tissue of the vocal folds

clinically normal vocal fold

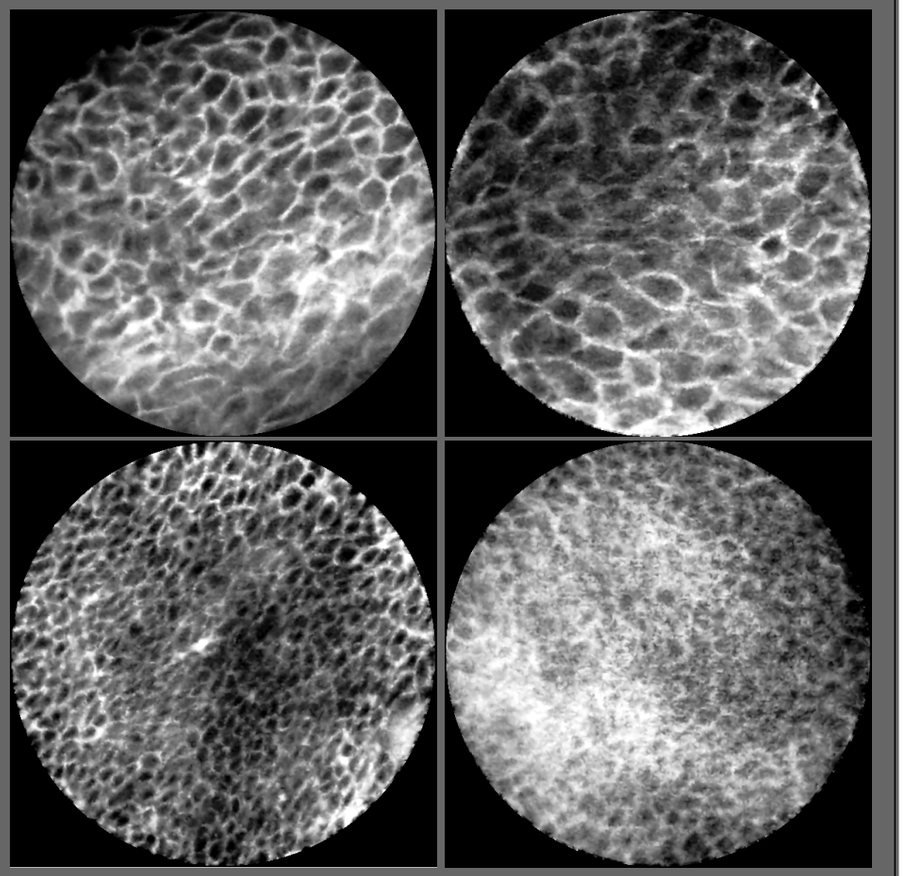

verified carcinoma

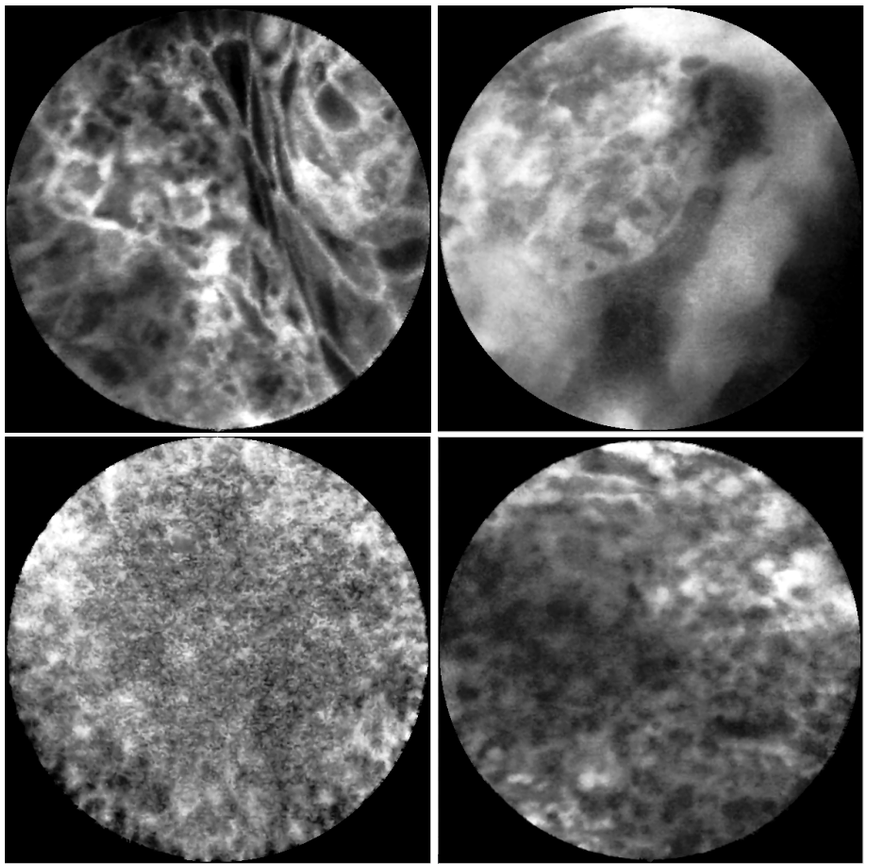

Our two data sets and the respective sites

Oral Cavity	Vocal Cords
12 patients	5 patients
116 sequences	73 sequences
7,879 images	4,425 images

- Epithelium similar in the vocal cords as in the oral cavity
- Different clinical crew
- Different hospital

Results (Leave 1 patient out X-Validation)

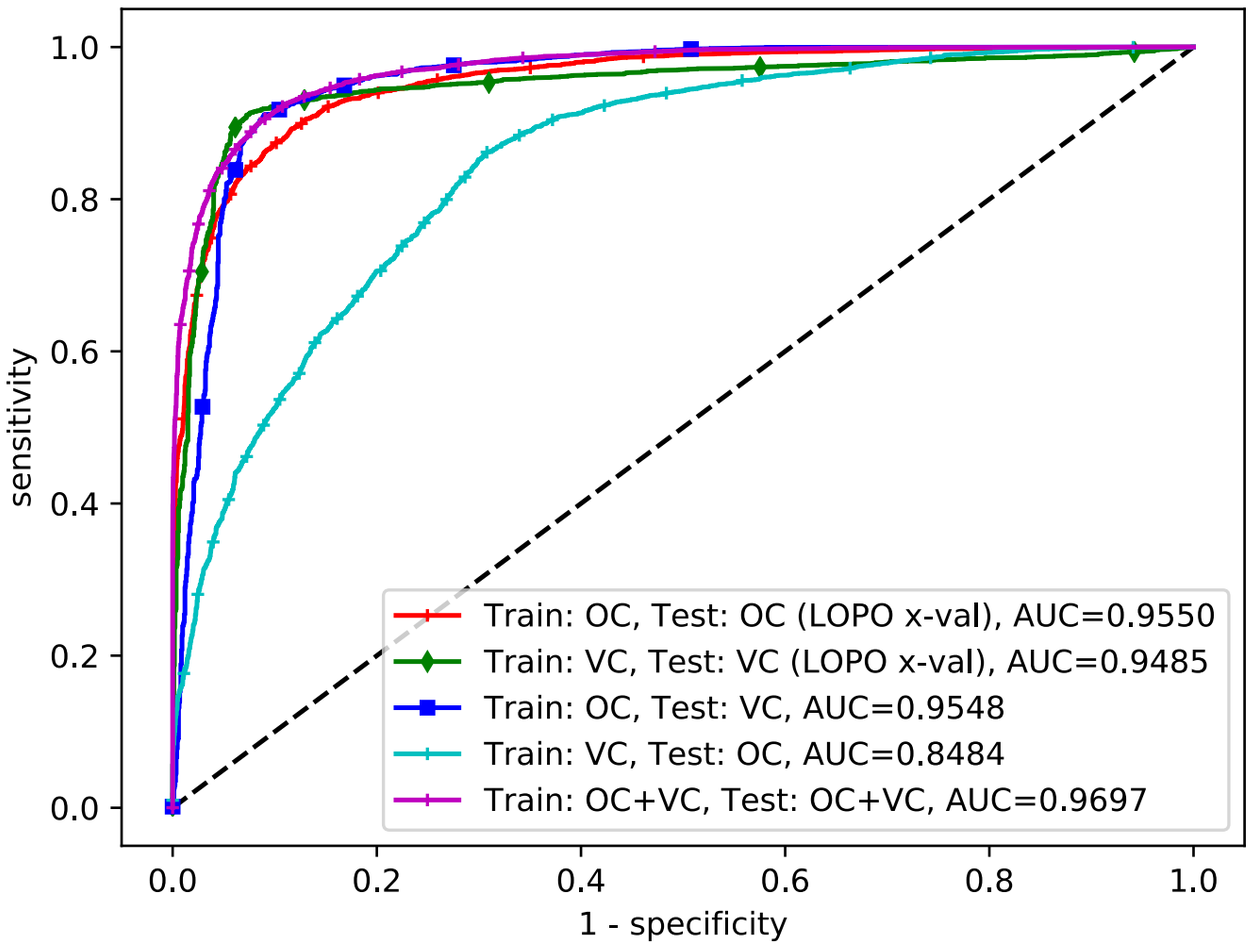

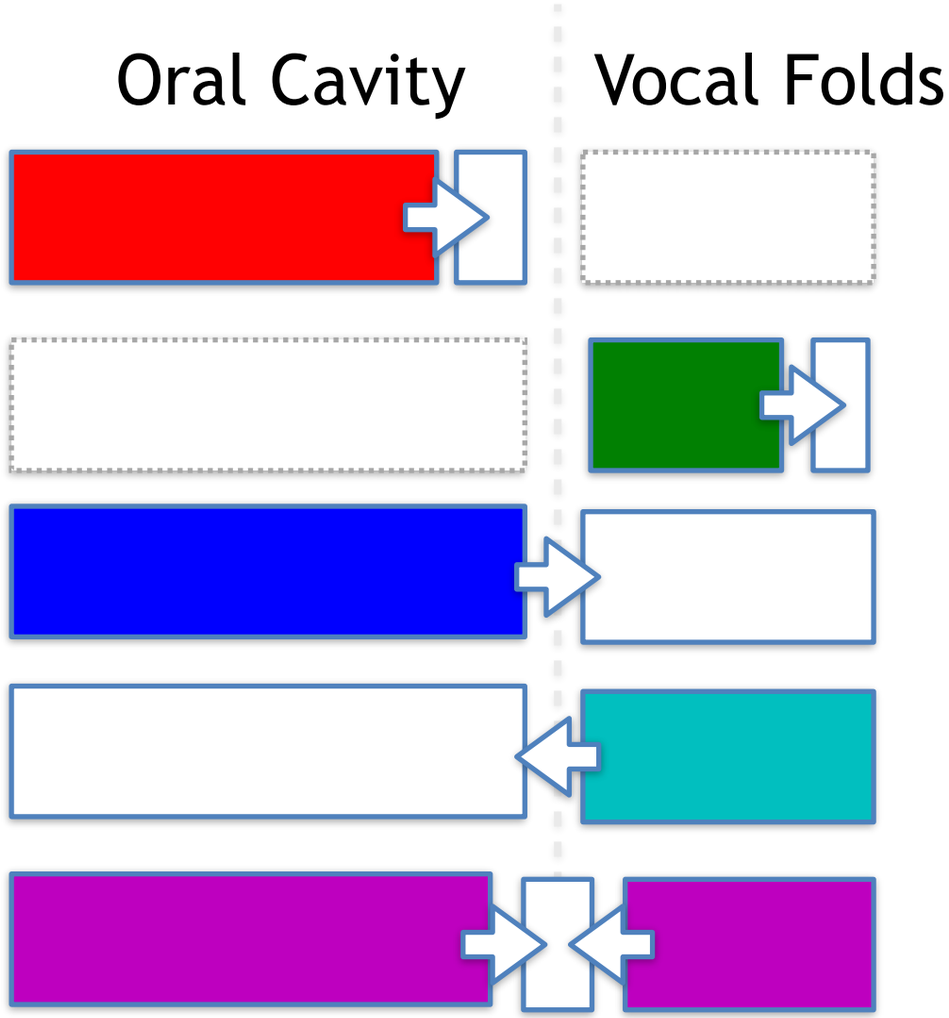

Why doesn't generalization from VC to OC work?

- **Cornification** prevalent only in parts of OC data set

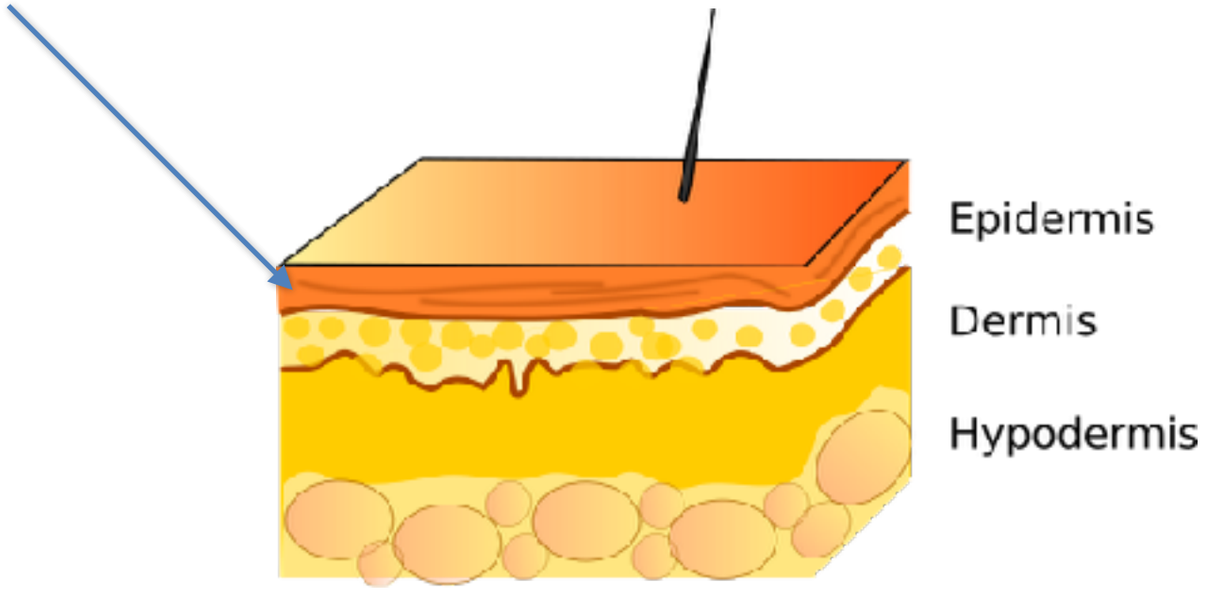

- not cornified:
  Vocal folds, inner lip, alveolar ridge (Rohen, 1994)
- cornified:
  hard palate, outer lip (Luellmann-Rauch, 2015)

Cornification leads to worsened SNR

- Raw pixel values are inductive of optical response
- Lower optical response leads to lower SNR
- Vocal folds data set shows generally higher median pixel values
- Restricted data set variance of VC data set hinders generalization to OC

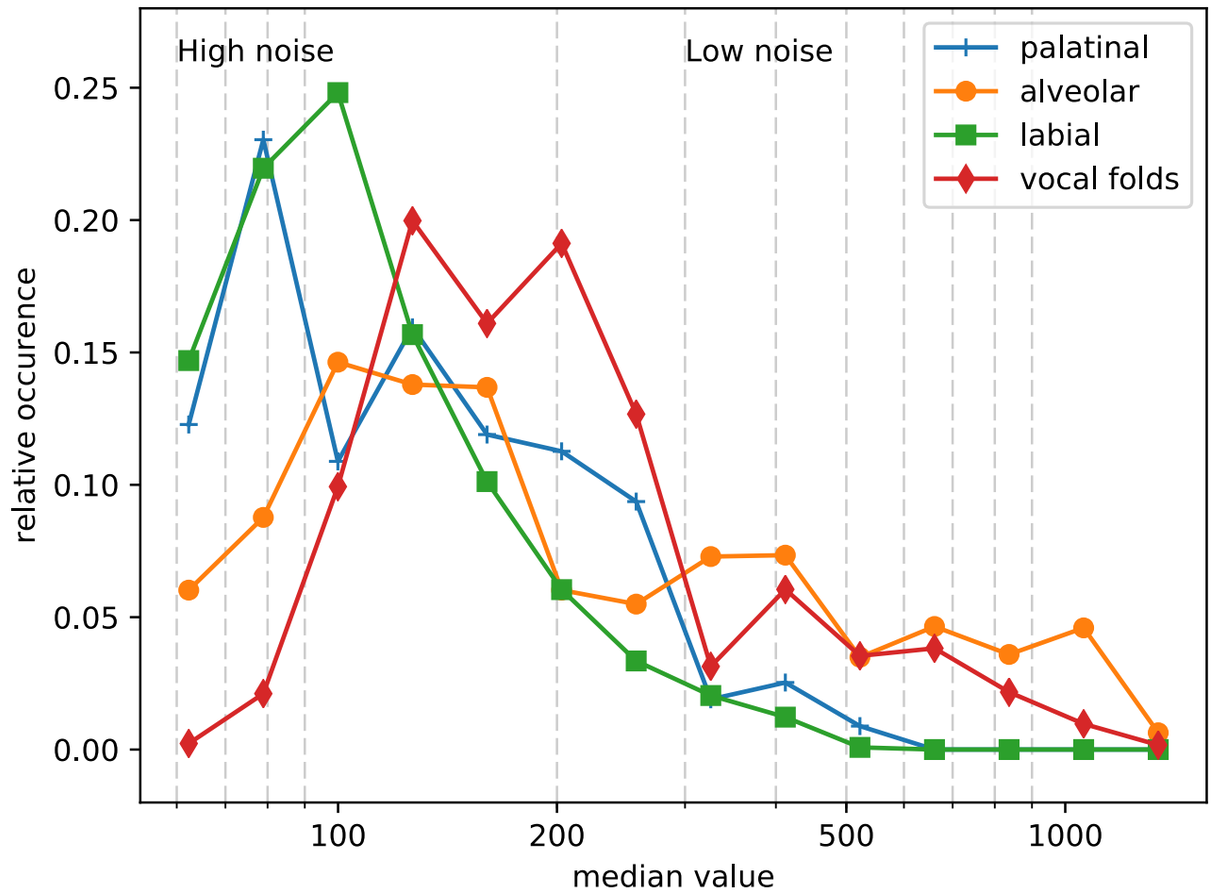

Detection Examples

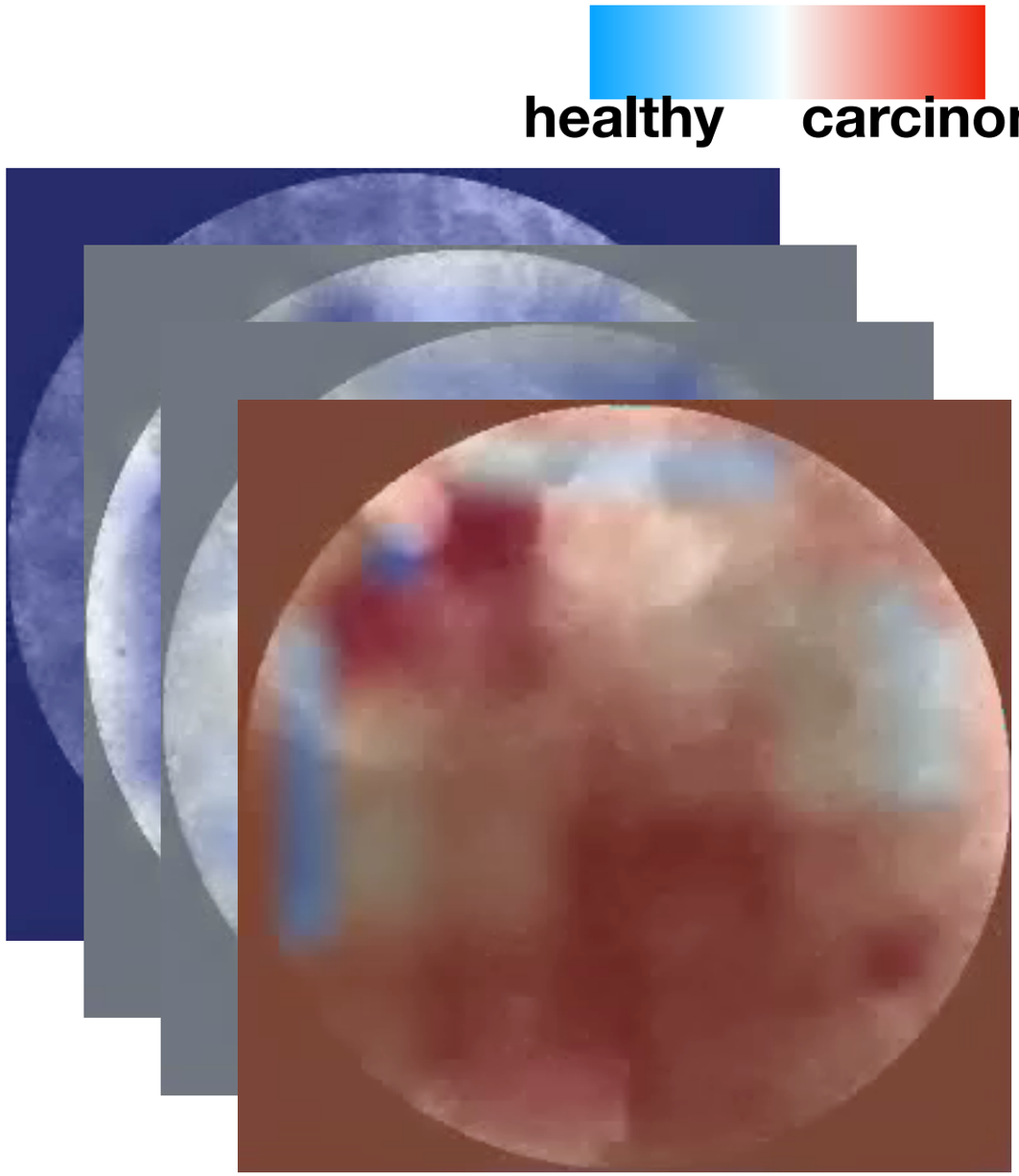

Discussion

- Questionable, if CLE alone is sufficient for assessment. (Goncalves et al., 2017, Oetter et al., 2016)
  - Potential to overlook tumors in greater depth
  - Combination with other optical techniques

- More CLE image data required for:
  - clinically acceptable sensitivity/specificity rates
  - proving generalization in a broader sense
  - especially histo-pathologically proven healthy images required

Outlook

- Robust artifact detection in CLE images
- Acquisition of more patient data in our group
- Whole sequence analysis

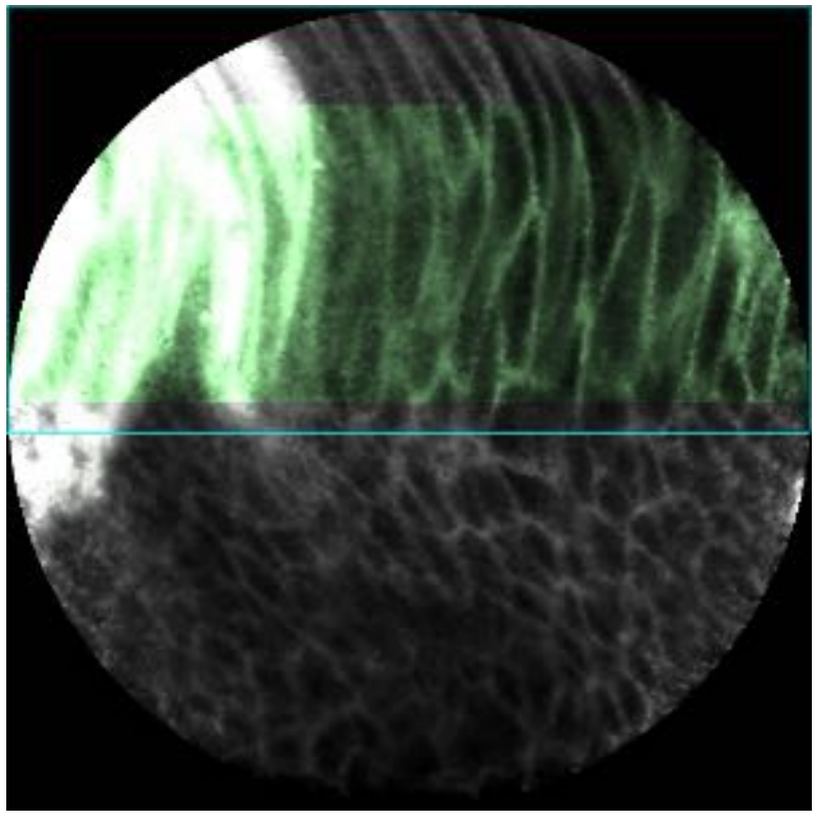

Conclusions

- Sometimes optimization of preprocessing yields much higher gains than network architecture
- Proposed method generalized well from one anatomical location to another and profited from joined data set
- Classifiers learnt from Oral Cavity CLE data generalize well on Vocal Fold CLE data



Thank you for listening!

Agaimy et al. (2012). Intraoperative frozen section diagnosis of head and neck tumors. DOI: 10.1007/s00292-012-1598-4

Aubreville et al. (2017). Automatic Classification of Cancerous Tissue in Laserendomicroscopy Images of the Oral Cavity using Deep Learning. DOI: 10.1038/s41598-017-12320-8

Cikojevic et al. (2008). Comparison of contact endoscopy and frozen section histopathology in the intra-operative diagnosis of laryngeal pathology. DOI: 10.1017/S0022215107000539

Ferlay et al. (2014). Cancer incidence and mortality worldwide, DOI:10.1002/ijc.29210

Forastiere et al. (2001). Head and Neck Cancer. DOI:10.1056/NEJMra001375

Goncalves et al. (2017). Value of confocal laser endomicroscopy in the diagnosis of vocal cord lesions. PMID: 29028105

Muto et al. (2004). Squamous cell carcinoma in situ at oropharyngeal and hypopharyngeal mucosal sites. DOI: 10.1002/cncr.20482

Nathan et al. (2014). Confocal Laser Endomicroscopy in the Detection of Head and Neck Precancerous Lesions. DOI: 10.1177/0194599814528660

Oetter et al. (2016). Development and validation of a classification and scoring system for the diagnosis of oral squamous cell carcinomas through confocal laser endomicroscopy. DOI: 10.1186/s12967-016-0919-4

Parkin et al. (2002). Global cancer statistics. PMID: 15761078

FRIEDRICH-ALEXANDER
UNIVERSITÄT
ERLANGEN-NÜRNBERG
FACULTY OF ENGINEERING

LEHRSTUHL FÜR
MUSTERERKENNUNG
PATTERN RECOGNITION LAB

Patch-based Carcinoma Detection on Confocal Laser Endomicroscopy Images - A Cross-Site Robustness Assessment

Marc Aubreville, Miguel Goncalves, Christian Knipfer, Nicolai Oetter, Tobias Würfl, Helmut Neumann, Florian Stelzle, Christopher Bohr, and Andreas Maier

in cooperation with:

FRIEDRICH-ALEXANDER
UNIVERSITÄT
ERLANGEN-NÜRNBERG
MEDIZINISCHE FAKULTÄT

Universitätsklinikum
Erlangen

UKE
HAMBURG

JG|U

SAOT
erlangen
graduate school in
advanced optical technologies