

Automatic Stent Detection in Intraoperative 2D Fluoroscopic Images for EVAR

Master's Thesis Introductory Talk

Fariba Azizmohammadi

30.05.2016

Supervisors: Katharina Breininger, Marcus Pfister, Markus Kowarschik,
Andreas Maier

Pattern Recognition Lab (CS 5)

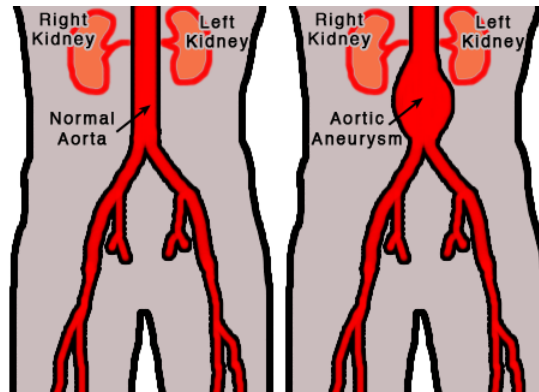


Content

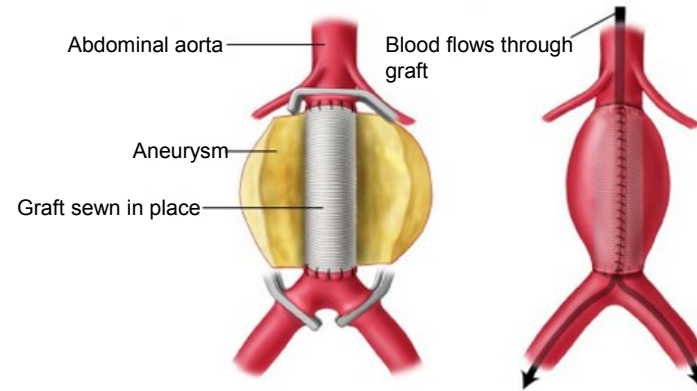
- Introduction
- Motivation
- Aims of this thesis
- Approach and results so far



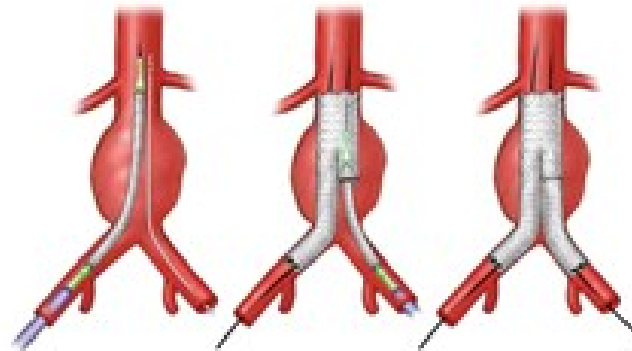
Introduction



Abdominal Aortic Aneurysm



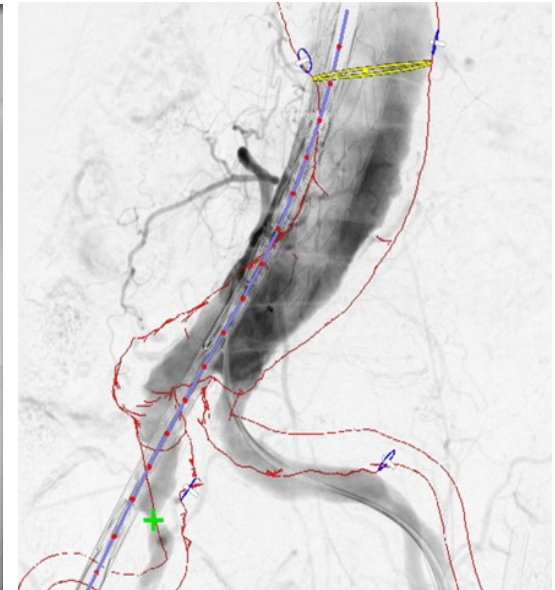
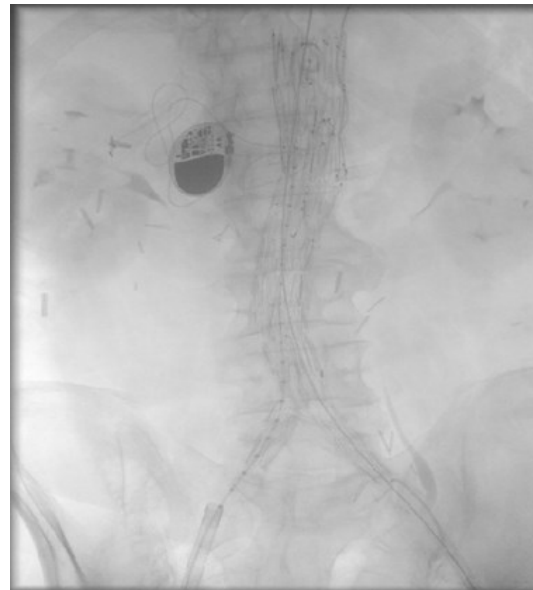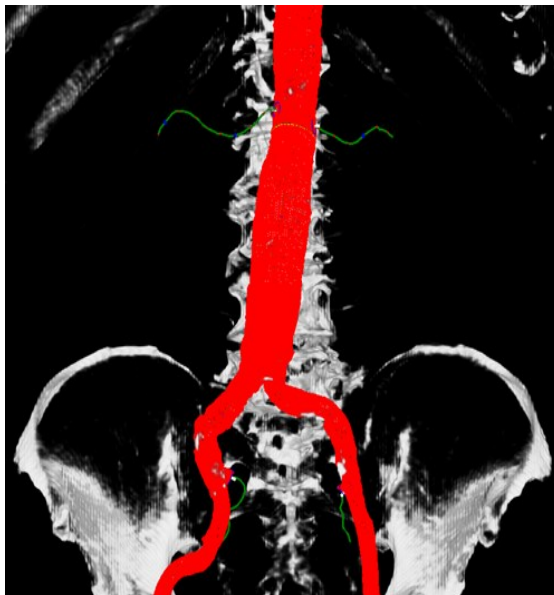
Traditional treatment



Endovascular Aneurysm Repair (EVAR)

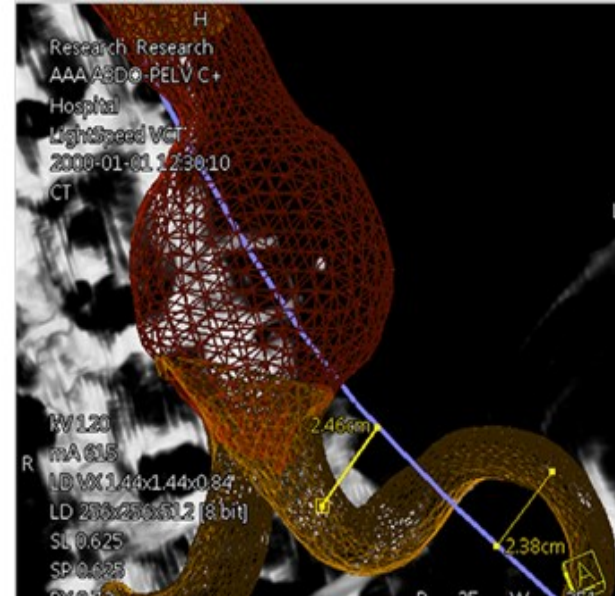
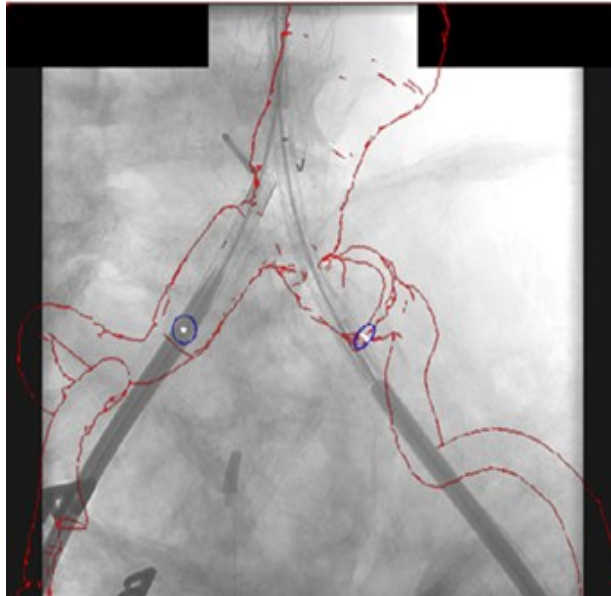EVAR procedure:

- Computed Tomography Angiography (CTA)
- Interventional X-ray imaging with an angiographic C-arm system
- Overlaying the pre-interventional 3D information with the 2D interventional X-ray

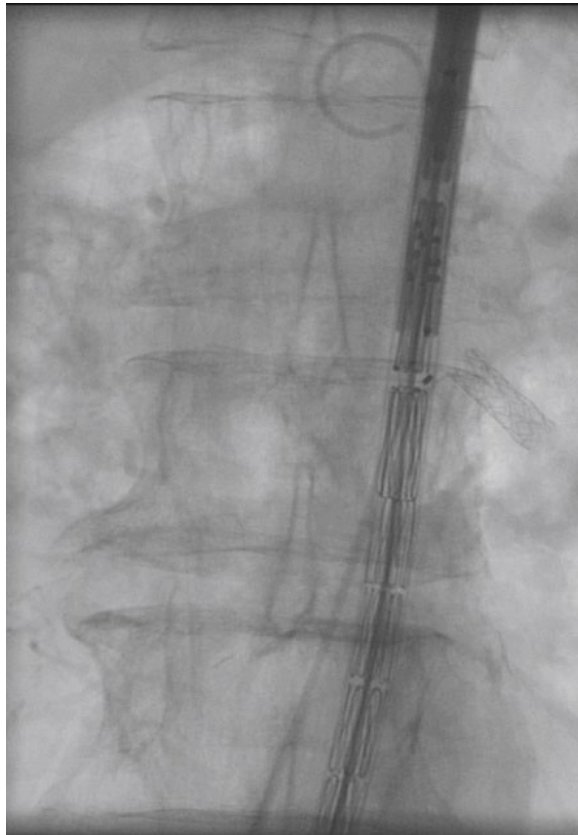


Motivation

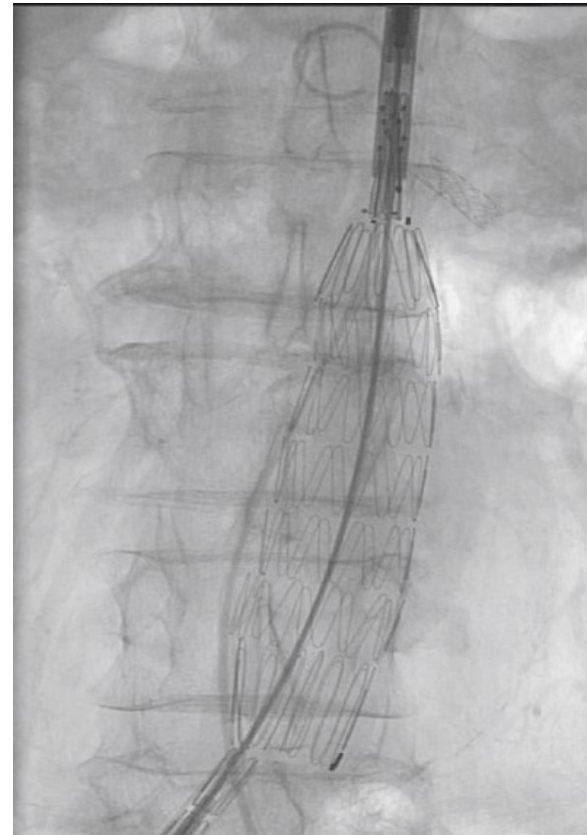
- Deformation caused by several devices
- Missing depth information in X-ray visualization
- Contrast agent injection during the interventions



Different Phases of EVAR



Folded stent graft delivery device



Deployed stent graft

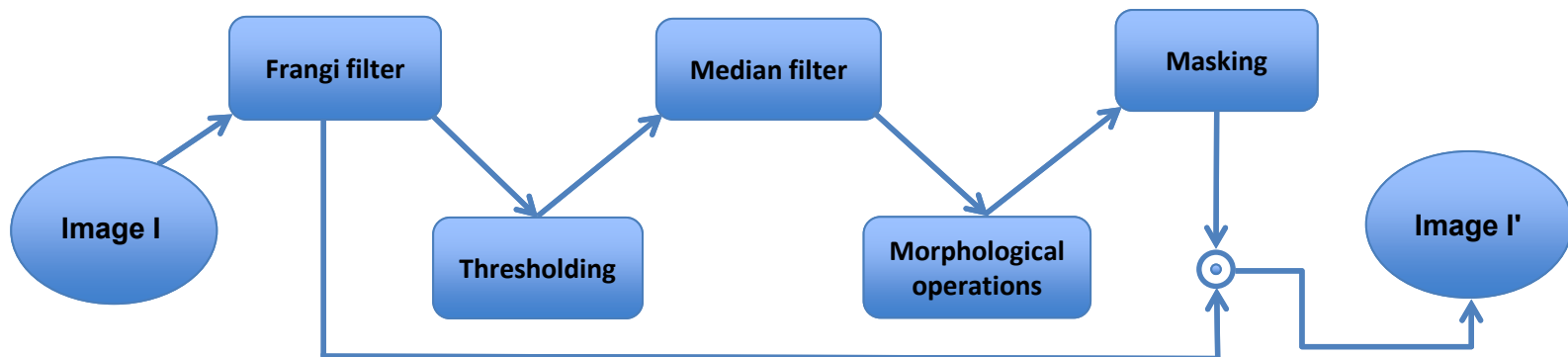
Aim of this master thesis

To provide an automatic detection and segmentation of the stent in un-contrasted fluoroscopic images, three steps are needed:

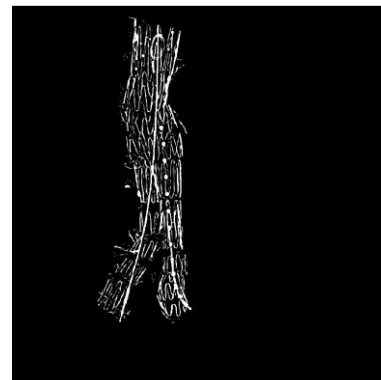
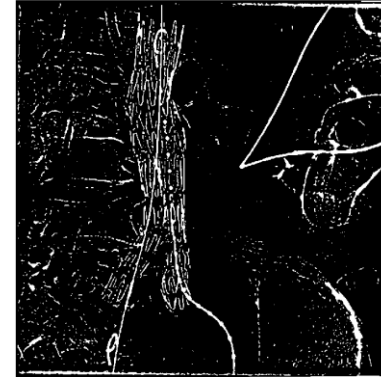
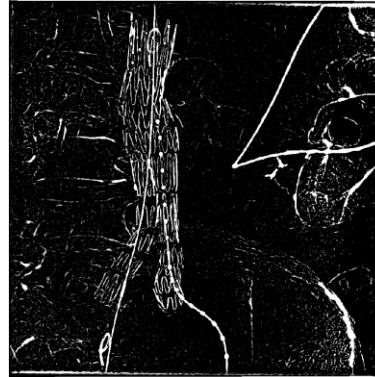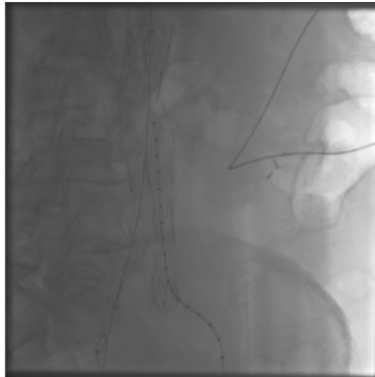
- Investigating preprocessing strategies to extract a region of interest that contains the deployed stent graft
- Segmenting the 2D outlines of the deployed stent graft
- Build a 3D model by extending the 2D detection

Results so far:

Preprocessing

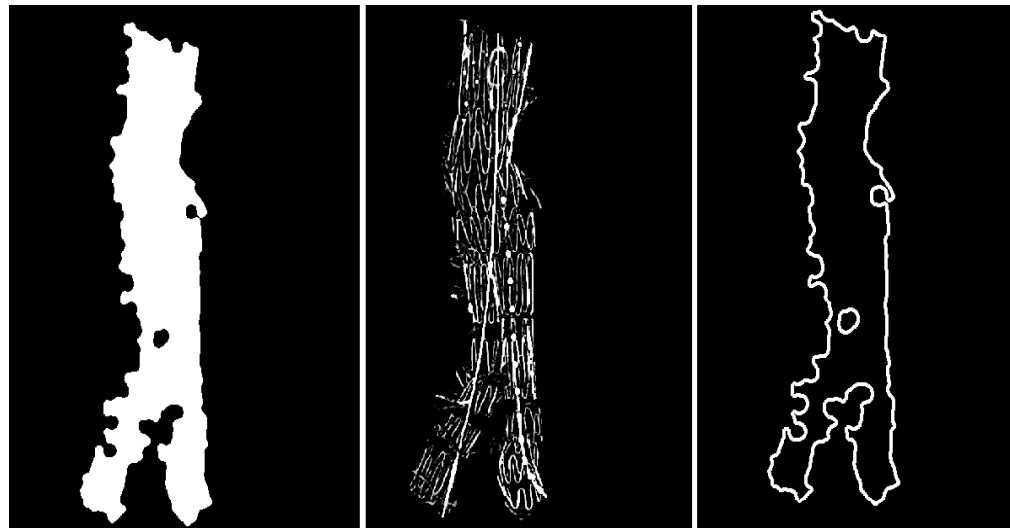


Preprocessing



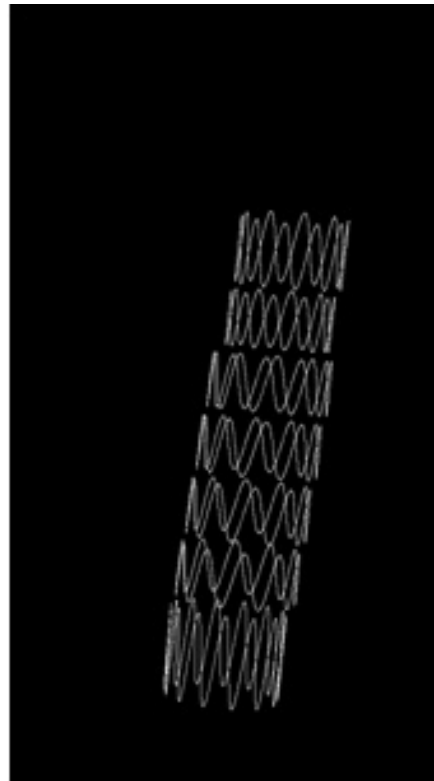
Segmentation

- Dilation and Erosion
- Convexity defects (convex hulls)
- Polygon Approximation



3D Model

Proposed idea for 3D model: Extending the 2D segmentation using cylindrical structure



To sum up

- **Detection and Segmentation of completely deployed stent (preserving the boundaries)**
- **Only one un-contrasted X-ray image**
- **Goal: Less time complexity and no need for frames**



Thank you for your attention!

